

## Research Article

***Morganella morganii* infection in blood parrot cichlid  
(*Amphilophus citrinellus* x *Paraneetroplus synspilus*) and its  
experimental pathogenicity in gold fish (*Carassius auratus*)  
treated with formalin**

**F. Ghiasi<sup>1\*</sup>, M. Nemati<sup>2</sup>, F. Pourahmad<sup>2</sup>, R. Farshgar<sup>3</sup>, M. Soltani<sup>4</sup>**

<sup>1</sup> Fisheries Department, Faculty of Natural Recourses, University of Kurdistan, Iran

<sup>2</sup> Department of Bacteriology, Faculty of Veterinary Medicine, Ilam University, Iran.

<sup>3</sup> Faculty of Veterinary Medicine, University of Razi, Kermanshah, Kermanshah, Iran

<sup>4</sup> Department of Aquatic Animal Health, Faculty of Veterinary Medicine, University of Tehran, Tehran, Iran.

Received: September 2024

Accepted: November 2024

**Abstract**

*Morganella morganii* is an opportunistic pathogen widely spread out within the intestinal tracts of mammals, humans and reptiles as a part of normal intestinal microbiota. The appearance of skin lesions in blood parrot cichlid, *Amphilophus citrinellus* x *Paraneetroplus synspilus*, were monitored in separate aquariums with O<sub>2</sub> 8 mg/L, pH 7.8, water hardness 145 mg/L CaCO<sub>3</sub>, and water temperature at 28 °C for two weeks. Initially, superficial lesions were appeared on the fish skin and gradually penetrated the muscles after one week and finally resulted in fish death. Samples from various organs including edges of skin lesions, muscle and kidney, spleen, and liver were taken under aseptic conditions, inoculated into tryptic soy agar incubated at 25°C and 37°C for 24 h.

**\*Corresponding author's email:**  
f.ghiasi@uok.ac.ir

The isolated bacteria from the kidney, spleen or liver were characterized using microbiological and molecular methods. Phenotypic and molecular assays resulted in the identification of *Morganella morganii* as the cause of skin lesions. Ninety apparently healthy goldfish (*Carassius auratus*) were challenged with isolated bacteria at  $5.4 \times 10^4$  CFU/mL as a bath for one hour under stress and non-stress conditions. Affected goldfish developed superficial lesions, fin necrosis, muscle necrosis, and mortality initiated six days after challenge and reached 60 % (18 fish) and 36.66 % (11 fish) in stressed and non-stressed goldfish, respectively after 14 days. This data confirmed *M. morganii* as the causative agent of freshwater fish aquariums, and thus need to be considered in the disease diagnosis in aquaculture activity.

**Keywords:** *Morganella morganii*, Freshwater fish, Stress, Blood parrot cichlid, Goldfish

## Introduction

*Morganella morganii* a Gram-negative enteric bacterium, has been regarded as an opportunistic pathogen though widely spread out within the intestinal tracts of humans, mammals, and reptiles as a part of normal intestinal microbiota. There have been several reports that *M. morganii* can cause sepsis, ecthyma, endophthalmitis, chorioamnionitis and more commonly urinary tract infections, wound infections, septic arthritis, meningitis, and bacteremia often with fatal results in humans (Senior and Voros, 1990; Choi *et al.*, 2002; Roels *et al.*, 2007; Cetin *et al.*, 2008; Singla *et al.*, 2010; Liu *et al.*, 2016; Li, *et al.*, 2018; Bandy, 2020; Bond and Stadler, 2020; Laupland, 2022; Maraki *et al.*, 2022). In pregnant women or neonates, *M. morganii* has been reported to cause a serious invasive infection (Ghosh *et al.*, 2009; Chang *et al.*, 2011; Bond and Stadler, 2020; Laupland, 2022; Maraki *et al.*, 2022). There are some reports of the emergence of third-generation cephalosporin-resistant *M. morganii* in a captive breeding dolphin (Park *et al.*, 2020).

In fish, *M. morganii* is one of the most prevalent and potent histamine producers (Kim *et al.*, 2001). It is most frequently found in the gills and skin, but rarely in the intestine and oral cavity of fish (Kim *et al.*,

2003). However, from the literature review available there is no evidence demonstrating this bacterium as a fish pathogen. In this study, we describe an infection caused by *M. morganii* in blood parrot cichlid fish (*Amphilophus citrinellus* x *Paraneetroplus synspilus*). To the best of our knowledge, this is the first report of a sporadic case of *M. morganii* infection in freshwater aquarium fish. Also, the virulence of the isolated strain was assessed in goldfish under stress conditions.

## Materials and methods

### Fish

This study was performed in the Aquarium Room at the University of Kurdistan, Iran. In October 2023, some red superficial lesions were observed on the flank of blood parrot cichlid fish which were kept in a 50 L glass aquarium. The affected fish were separated from the healthy ones and were kept in separate aquariums supplied with dechlorinated water (O<sub>2</sub> 8 mg/L, pH: 7.8, water hardness 145 mg/L CaCO<sub>3</sub>, temperature 28°C). One week later, red lesions penetrated muscles and affected demonstrated abnormal movement, loss of balance and death observed soon after lethargy.

### Bacteriological examinations

Samples from various organs of five dead fish including muscle and kidney were obtained under aseptic conditions, inoculated on tryptic soy agar and incubated at 25°C and 37°C for 24 h. The grown colonies were subjected to Gram staining before being grown on eosin methylene blue (EMB) agar for further characterization.

### Molecular assay

The isolated bacteria were identified by partial 16S rRNA gene sequencing, described by Spanggaard *et al.* (2000). Briefly, a loopful of an overnight culture on EMB was used for DNA extraction using boiling method (a bacterial colony was added to a 100 mL of TE buffer before being heated for 15 min. The sample was centrifuged at 13000 g for 2 min, and the supernatant containing bacterial DNA was used for PCR assay. Using simple boiling method, partial amplification of the 16S rRNA gene was performed using the primers 008F (5'- AGA GTT TGA TCC TGG CTC AG-3') and 517R (5'- ATT ACC GCG GCT GCT GG-3') (Taq, Denmak). PCR was undertaken using a DNA thermal cycler (Eppendorf); a 25 µL reaction mixture contained 1 µL MgCl<sub>2</sub>, 0.2 µL Taq

DNA polymerase, 0.5µL dNTPs, 2 µL of each primer, 3 µL DNA sample and double distilled water 15.8 µL. The PCR conditions were as follows: an initial incubation at 94°C for 5 min followed by 34 cycles of denaturation at 94°C for 30 S, annealing at 55°C and elongation at 72°C for 1 min with final extension for 5 min at 72°C. After amplification, 5 µL of the reaction products were mixed with 3 µL of the sample buffer (50% glycerol) and electrophoresis was performed. The gels were visualized under UV light and photographed. Gene Ruler™ 100 bp DNA Ladder Plus (MBI Fermentas, St. Leon-Rot, Germany) was used as a DNA size marker.

### 16S rRNA gene sequencing

PCR amplicons were purified from the remaining reaction mix using Qiaquick purification kit as described by the supplier (Qiagen, UK), and quantified using an Eppendorf spectrophotometer. Both strands were sequenced using the PCR primers. Sequencing was performed commercially by Macrogen (South Korea). Both forward and reverse sequences were assembled and edited using the SeqMan II module of Lasergene, Version 6 (DNASTAR, Inc., Madison, USA). The resulting consensus sequences were compared with published

nucleotide sequences using Nucleotide BLAST (blastn) analysis (<http://blast.ncbi.nlm.nih.gov/Blast.cgi>).

### Antimicrobial susceptibility assay

An antibiotic sensitivity test was conducted to determine the best antibiotic affecting the isolates. This test was performed using the Kirby-Bauer disk-diffusion method using Muller Hinton agar. The susceptibility of the isolated strains was assessed using ciprofloxacin (5 µg), norfloxacin (5 µg), tetracycline (30 µg) and penicillin (10 µg) according to the guidelines of the clinical and laboratory standards institute, and results obtained 24 h post-incubation at 30C (Maraki *et al.*, 2022).

### Virulence assay

Ninety healthy goldfish average weight 12 g were randomly divided into three groups of 10 fish each in 50 L glass aquariums in triplicates. The aquariums were supplied with dechlorinated water (with O<sub>2</sub>: 8mg/l, pH: 7.8, water hardness: 145 mg/l CaCO<sub>3</sub>, temperature 20°C) and continuous aeration. Group one was considered as the control group. Group two f was bath challenged with a suspension of isolated bacteria with count  $5.4 \times 10^4$  CFU /mL for one hour. The second passage of the bacteria which were grown in tryptic soy broth for 48 h at 25°C

was used for the bacterial challenge test. Counting the colonies was confirmed by plate count method.

In group three, first fish were exposed to formalin at 250 ppm for one hour before being challenge with the bacterium at  $5.4 \times 10^4$  CFU /mL for one hour. The challenged fish were monitored for 2 weeks, fed 2% body weight with commercial feed, and Clinical signs and mortality were checked daily. Samples of kidney, liver, and spleen of the dead fish were obtained under aseptic conditions and inoculated on EMB agar to confirm the cause of mortality. Virulence bioassay conducted according ethic roles of Univiersity of Tehran.

A one-way analysis of variance (ANOVA; SPSS, 16.0) was used to determine whether significant variation between the treatments existed. Differences between means were determined and compared with Duncan test at significance level of ( $p<0.05$ ). The data were reported as a mean± standard error.

### Results

Post-mortem examination of the affected blood parrot cichlid showed diffuse petechial in the liver and kidney which were also enlarged and hyperemic (Fig. 1).



**Figure 1.** Skin lesions caused by *M. morganii* in blood parrot cichlid.

### Phenotypic characteristics of the isolated bacterial strains

The grown colonies were circular white-opaque on TSA. In Gram staining they were straight rods and Gram negative (0.6-1.6  $\mu\text{m}$ ) without polymorphism. The bacterium produced pink colonies on eosin methylene blue (EMB) agar (lactose negative). Based on the biochemical assays this isolated bacterium was identical to *Citrobacter* spp. and *Morganella* spp (Table 1).

### Antimicrobial susceptibility assay

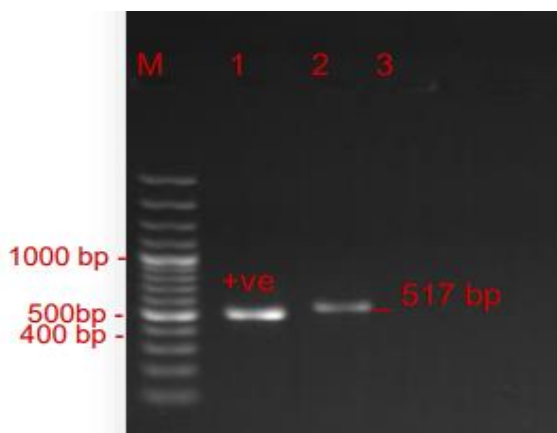
The isolated bacteria from kidney, spleen and muscle were sensitive to ciprofloxacin and norfloxacin, but were resistant to tetracycline and penicillin.

### PCR assay

A fragment of DNA with a size of 517 bp was detected in all three isolates from kidney, spleen and muscle tissues (Fig. 2).

**Table 1.** Phenotypic and biochemical features of the isolated bacteria from kidney and muscles of blood parrot cichlid fish.

Characteristics of isolated bacteria	Result		
	Kidney	Muscle	Spleen
Gram staining	-	-	-
Catalase	+	+	+
Oxidase	-	-	-
Indole	+	+	+
Motility	+	+	+
Lactose fermentation	-	-	-
Lysine	-	-	-
Citrate	-	-	-
Methyl red	+	+	+
Vogues Proskauer	-	-	-
Urea	+	+	+
H <sub>2</sub> S on SIM	-	-	-
Growth at 25°C	+	+	+
Growth at 37°C	+	+	+



**Figure 2.** PCR product of bacterial isolates. M= 100bp marker, 1=positive control, 2= test sample, 3= negative control.

The 16S-rRNA sequence of the isolated strains was compared and aligned with the 16S-rRNA sequences of other bacterial species available in GenBank database. The bacterial isolates exhibited 98–100% similarity with other available *M. morganii* strains. The partial 16S rRNA gene sequence of isolates was determined and submitted to the GenBank database (accession number: KF110789). The 16S rRNA sequence of our isolates was similar to the corresponding sequence from strain ZJB-09203 (accession no: KC250021). The

results of the 16S rRNA sequencing of isolates demonstrated that the bacterium that was isolated to be more than 99% similar to *M. morganii*. The target sequence was analyzed with all available 16S rDNA sequences of *M. morganii* in the GenBank.

### Pathogenicity bioassay

Affected goldfish demonstrated skin lesions on different body parts including lateral side, pectoral area and dorsal site (saddle back lesions) (Fig. 3). Mortality was initiated 6 days post challenge. Internally affected fish developed hyperemia in their internal organs such as liver and kidney. The mortality rates in stressed and non-stressed fish reached in 60 % (18 fish) and 36.66 % (11 fish), respectively. Also, no mortality was seen in control fish (challenged with sterile PBS). *M. morganii* was re-isolated from the kidney, spleen, liver and muscle of affected goldfish and confirmed by phenotypic and PCR assays.



**Figure 3.** Experimental infection by *M. morganii* in goldfish showing skin lesions on the lateral and dorsal areas of affected fish.

## Discussion

*Morganella morganii* is a facultative anaerobic rod gram negative enteric bacterium which was first isolated from a pediatric fecal culture (Morgan, 1906). The presence of *M. morganii* in the intestinal tracts of humans, mammals and reptiles as normal flora has been frequently reported Zhao *et al.* (2012). In fish, *M. morganii* is one of the most prevalent and potent histamine producers (Kim *et al.*, 2001) commonly associated with gills and skin (Kim *et al.*, 2003). Zhao *et al.* (2012) confirmed that *M. morganii* causes a fatal infection in chickens. In some countries like Iran, Tajikistan, Afghanistan people use goldfish profusely as a symbol during New Year celebrations after which they are released them into lakes and rivers, hence fish farmers must be informed of these risks.

To our knowledge, there is no evidence that this bacterium could be pathogenic to fish. In this study, by isolation and phenotypic identification of the bacteria and 16S rRNA gene sequencing of the isolated strains, we confirmed that *M. morganii* is able to attack blood parrot cichlid and goldfish causing morbidity and mortality. In the current study, the experimental gold fish were affected by *M. morganii* under both stress and non-stress conditions, and

demonstrated clinical sign and mortality and *M. morganii* was re-isolated from the kidney or spleen of affected fish. Similar clinical signs were observed under two different conditions, but the mortality rate in the group subjected to stress was considerably higher than non-stress group. *M. morgani* was previously introduced as an opportunistic organism caused by *Flavobacter cloumnare*. In gold fish exposed to formalin stress, the mortality rate was significantly greater than that of un-stressed fish. Thus, stress can affect the virulence of the pathogen. Formalin treatment clears the fish of ecto-parasites but it might leave the fish become more susceptible to opportunistic pathogens as a result of injuries to the skin caused by formaldehyde treatment and simultaneously leave the fish in an immuno-suppressed stage that result in a high level of cortisol secretion (Pickering and Pottinger, 1989). Increasing plasma cortisol is reported in Bonytail (*Gila elegans*) subjected to formalin and handling stress (Sykes *et al.*, 2011). In rainbow trout, elevating plasma cortisol was described by Jørgensen *et al.* (2007) to be associated with *I. mulifiliis* infection as well as formalin bath treatment. These findings imply that stress factors might play a role in pathogenicity of *M. morganii*.

The response of the innate immune system might be modified by external stimuli, particularly stressors, which are most often known to induce immunosuppressive effects in fish (Tort, 2011). Thus, the stressed fish can exhibit a decreased activity in complement, hemagglutination, and reduction of circulating lymphocytes as mentioned by Engelsma *et al.* (2003). Decreases in C3 complement component protein levels (Douxflis *et al.*, 2011) and expression of some immune-relevant genes (Kim *et al.*, 2003) have also been reported. Such effects can explain a higher susceptibility to the pathogen in stressed goldfish.

*M. morganii* can be a pathogenic agent not only for fish and birds but also for mammals, including humans posing a threat to public health, particularly a threat to people who come into contact with disease (Li *et al.*, 2018; Laupland *et al.*, 2022). Interestingly strains of *M. morganii* have been reported from the infected leeches (*Hirudo medicinalis*) with a considerable death and morbidity rate (70%) and severe clinical abnormalities in leeches (Rahmati Holasoo *et al.*, 2022). There is no doubt that other factors particularly water quality fluctuations are involved in *M. morganii* virulence and disease outbreaks and that the number of

host species is increasing. Therefore, greater monitoring efforts must be put in place in the future to evaluate the actual mechanisms of this pathogen in fish.

## Acknowledgment

This study was partially supported by The Universities of Kurdistan and Ilam.

## Competing Interests

The authors have no relevant financial or non-financial interests to disclose.

## Author Contributions

All authors contributed to the study conception and design. Material preparation, data collection and analysis were performed by Farzad Ghiasi, Fazel Pourahamd, Mostafa Nemati and Rozhin Farshgar. The first draft of the manuscript was written by Farzad Ghiasi and Rozhin Farshgar. Final revised was carried out by Mehdi Soltani. All authors read and approved the final manuscript.

## Data Availability

The datasets generated during and/or analyzed during the current study are available from the corresponding author on reasonable request.



## References

- Ahmad, M. G., Kulshreshtha, J. B. and Singh, G., 2011. Growth and pigment profile of *Spirulina platensis* isolated from Rajasthan, India. *Research Journal of Agricultural Sciences*, 54(1), 1, pp. 83-86.
- Bandy, A. 2020. Ringing bells: *Morganella morganii* fights for recognition. *Public Health*, 182, 45–50. <https://doi.org/10.1016/j.puhe.2020.01.016>
- Bond, E.; Stadler, J.A. 2020. Subdural empyema caused by *Morganella morganii*. *Surg. Neurol. Int.*, 11, 216. doi: 10.25259/SNI\_136\_2020
- Cetin M, Ocak S, Kuvandik G, Aslan B, Temiz, M. Aslan A. 2008. *Morganella morganii* associated arthritis in a diabetic patient. *Advances in Therapy* 25, 240-244. <https://doi.org/10.1007/s12325-008-0026-x>
- Chang HY, Wang SM, Chiu NC, Chung HY, Wang HK. 2011. Neonatal *Morganella morganii* sepsis: a case report and review of the literature. *Pediatrics International* 2011; 53, 121-123. <https://doi.org/10.1111/j.1442-200X.2010.03241.x>
- Choi JH, Yoo, H S, Park, JY, Kim, YK, Kim E, Kim DY. 2002. Morganelliasis pneumonia in a captive jaguar. *Journal of Wildlife Diseases* 38, 199-201. <https://doi.org/10.7589/0090-3558-38.1.199>
- Doux fils J, Mathieu C, Mandiki S N , Milla S, Henrotte E, Wang N, Vandecan M, Dieu M, Dauchot N, Pigneur LM, Li X, Rougeot C, Mélard C, Silvestre F, Van Doninck K, Raes M, Kestemont P, 2011. Physiological and proteomic evidences that domestication process differentially modulates the immune status of juvenile Eurasian perch (*Perca fluviatilis*) under chronic confinement stress. *Fish and Shellfish Immunology*, 31, 6, 1113–1121. <https://doi.org/10.1016/j.fsi.2011.10.001>
- Engelsma M Y, Hougee S, Nap D, Hofenk, M , Rombout, JH, van Muiswinkel WB, Lidy V, Kemenade BM. 2003. Multiple acute temperature stress affects leucocyte populations and antibody responses in common carp, *Cyprinus carpio* L., *Fish Shellfish Immunology*, 15, 5, 397–410. [https://doi.org/10.1016/S1050-4648\(03\)00006-8](https://doi.org/10.1016/S1050-4648(03)00006-8)
- Ghosh S, Bal AM, Malik I, Collier A. 2009. Fatal *Morganella morganii* bacteraemia in a diabetic patient with gas gangrene. *Journal of Medical Microbiology*, 58, 965-957. <https://doi.org/10.1099/jmm.0.008821-0>
- Jørgensen TR, Larsen TB, Jørgensen LG, Bresciani J, Kania PW, Buchmann K. 2007. Characterisation of a low pathogenic form of *Gyrodactylus salaris* from rainbow trout. *Diseases of Aquatic Organisms* 73, 235–244. <https://doi.org/10.3354/dao073235>

- Kim SH, Field K G, Chang D S, Wei CI, An H. 2001. Identification of bacteria crucial to histamine accumulation in pacific mackerel during storage. *Journal of food protection*, 64, 10, 1556-1564. <https://doi.org/10.4315/0362-028X-64.10.1556>
- Kim S H, An. H, Wei C I, Visessanguan W, Benjakul S, Morrissey MT, Su YC, Pitta TP. 2003. Molecular detection of a histamine former, *Morganella morganii*, in albacore, mackerel, sardine, and a processing plant. *Journal of Food Science*, 68, 2, 453–457. <https://doi.org/10.1111/j.1365-2621.2003.tb05693.x>
- Laupland, K.B.; Paterson, D.L.; Edwards, F.; Stewart, A.G.; Harris, P.N. 2022. *Morganella morganii*, an Emerging Cause of Bloodstream Infections. *Microbiol. Spectr.*, 10, e00569-22. <https://doi.org/10.1128/spectrum.00569-22>
- Li, G.; Niu, X.; Yuan, S.; Liang, L.; Liu, Y.; Hu, L.; Liu, J.; Cheng, Z. 2018. Emergence of *Morganella morganii* subsp. *morganii* in dairy calves, China. *Emerg. Microbes Infect.*, 7, 1–12. <https://doi.org/10.1038/s41426-018-0173-3>
- Liu, H.; Zhu, J.; Hu, Q.; Rao, X. 2016. *Morganella morganii*, a non-negligent opportunistic pathogen. *Int. J. Infect. Dis.* 2016, 50, 10–17. <http://doi.org/10.1016/j.ijid.2016.07.006>
- Maraki, S.; Mantadakis, E.; Spervovasilis, N.; Mathioudaki, A.; Peristeris, G.; Alexakis, K.; Kofteridis, D.; Samonis, G. *Morganella morganii*. 2022. Infections in a Greek University Hospital: Patient Characteristics, Antimicrobial Susceptibilities, and Outcomes. *Infect. Dis. Clin. Pract.* 2022, 30, e1110. <https://doi.org/10.1097/IPC.0000000000001110>
- Morgan HR. 1906. Upon the bacteriology of the summer diarrhoea of infants. *Br Med J* 1907; 2:908–12. <https://doi.org/10.1177/003591570900201304>
- Park, S.Y.; Lee, K.; Cho, Y.; Lim, S.R.; Kwon, H.; Han, J.E.; Kim, J.H. 2020. Emergence of third-generation cephalosporin-resistant *Morganella morganii* in a captive breeding dolphin in South Korea. *Animals*, 10, 2052. <https://doi.org/10.3390/ani10112052>
- Pickering AD, Pottinger TG. 1989. Stress responses and disease resistance in salmonid fish: Effects of chronic elevation of plasma cortisol. *Fish Physiology and Biochemistry*, 7: 253–258. <https://doi.org/10.1007/BF00004714>
- Rahmati Holasoo, H.; Tamai, I.A.; Brück, W.M.; Pakbin, B.; Asiri, A.; Azizi, A. 2022. *Morganella Morganii* Infection in *Hirudo Medicinalis* (Iran): A Case Report. *Vet. Sci.* 2022, 9, 562. <https://doi.org/10.3390/vetsci9100562>
- Roels S, Wattiau P, Fretin D, Butaye P and Vanopdenbosch E. 2007. Isolation of

*Morganella morganii* from a domestic rabbit with bronchopneumonia. *Veterinary Record*, 161, 15, 530. <http://dx.doi.org/10.1136/vr.161.15.530>

Senior BW, Voros S. 1990. Protein profile typing: a new method of typing *Morganella morganii* strains. *Journal of Medical Microbiology*, 33, 259-64. <https://doi.org/10.1099/00222615-33-4-259>

Singla N, Kaistha N, Gulati N, Chander J. 2010. *Morganella morganii* could be an important intensive care unit pathogen. *Indian Society of Critical Care Medicine*, 14, 3, 154-155. <https://doi.org/10.4103/0972-5229.74176>

Sykes CL, Caldwell C A, Gould WR. 2011. Physiological Effects of Potassium Chloride,

Formalin, and Handling Stress on Bonytail. *North American Journal of Fisheries Management*, 31,2, 291-298. <https://doi.org/10.1080/02755947.2011.576201>

Tort L. 2011. Stress and immune modulation in fish, *Developmental & Comparative Immunology*, 35, 12, 1366–1375. <https://doi.org/10.1016/j.dci.2011.07.002>

Zhao C, Tang N, Wu Y, Zhang Y, Wu Z, Li W, Qin X, Zhao J, Zhang G. 2012. First report of fatal *Morganella morganii* infections in chickens. *Vet Microbiol*, 156, 452-455. <https://doi.org/10.1016/j.vetmic.2011.11.021>