

# Practical effect of calcium oxide and sodium chloride on the control and treatment of *Ichthyophthirius multifiliis* in Gold fish (*Carassius auratus*) farms

M. Rahanandeh<sup>1\*</sup>, M. Rahanandeh<sup>2</sup>

<sup>1</sup> Guilan Agricultural and Natural Resources Research and Education Center Agricultural Research, Education and Extension Organization (AREEO), Rasht, Iran

<sup>2</sup> Department of Genetics, Faculty of Biological Sciences, North Tehran Branch, Islamic Azad University, Tehran, Iran

Received: May 2020

Accepted: August 2020

## Abstract

In this study, seven aquaria were designated and 25 gold fish infected with Ich (*Ichthyophthirius multifiliis*) parasite were introduced to each of them. Different levels of Calcium oxide (13, 14 and 15 mg L<sup>-1</sup>) were used in three treatments of the group No 1. Three treatments in the second group received sodium chloride (1500, 2000, and 2500 mg L<sup>-1</sup>) with 72 h intervals respectively. In this study, the effectiveness of two drugs was compared through examining the normality of the data by Kolmogorov-Smirnov test and one-way analysis of variance at the level of 0.5%. The data analysis was carried out via Duncan's discriminate test to compare the treatments with each other along with further analysis of data using SPSS 20 statistical software.

In order to determine the effectiveness of drugs, wet slides were prepared from different parts of skin, fins and gills during the experimental stages and were subjected to microscopic observation. The results of this study showed that Cao 15 mg L<sup>-1</sup> had the greatest effect on the fish gills and the fish showed the least parasites in this area ( $4.17 \pm 2.48$ ) ( $p < 0.05$ ). The use of calcium oxide (Cao 14 mg L<sup>-1</sup>) and sodium chloride (NaCl 2500 mg L<sup>-1</sup>) had similar effects on the parasite in the gill area ( $p > 0.05$ ).

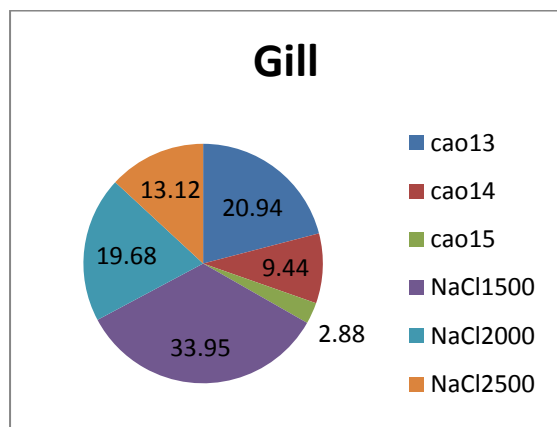
**Keywords:** Gold fish, parasites, *Ichthyophthirius multifiliis*, calcium oxide, sodium chloride

## Introduction

Today, ornamental fish play a very important role in creating employment opportunities for people including university graduates and can be used in trade. The East Asian countries such as China, Malaysia and Singapore, have high income

\*Correspondence M. Rahanandeh, Guilan Agricultural and Natural Resources Research and Education Center Agricultural Research, Education and Extension Organization (AREEO), Rasht, Iran (e-mail: rahanandeh1340@gmail.com)

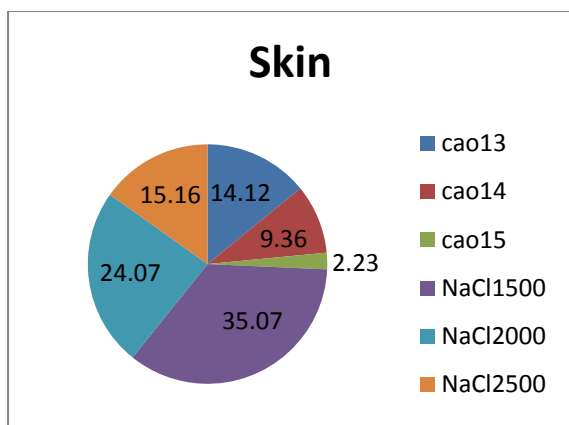
generation compared to other countries in terms of reproduction and breeding of ornamental fish (Christoffersen *et al.*, 2017; Heinecke and Buchmann, 2009; Jalali, 1998) (Fig 1).



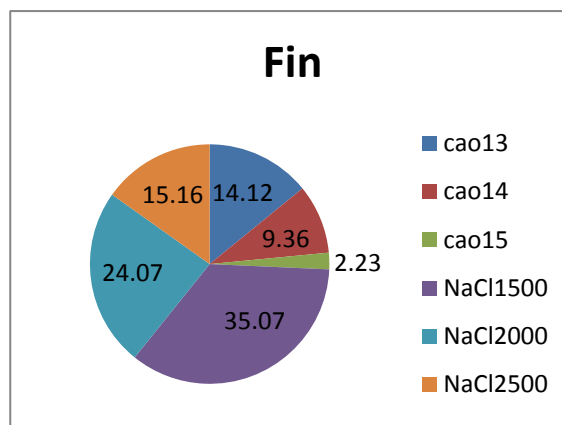
**Figure 1.** Percentage of effects of two drugs, calcium oxide and sodium chloride, on parasite Ich in the gills.

In Iran, the ornamental fish breeding is a newly-developed industry which is growing. Naturally, the issue of ornamental fish breeding becomes important when health management is taken into account. Fish diseases has always been important, either in aquaria that are more closely monitored or in breeding ponds that have a relatively high density (Alam *et al.*, 2014; Christoffersen *et al.*, 2017; Noga, 2010). The protozoan *Ichthyophthirius multifiliis* in fish is called the white parasite or Ich. Its life cycle alternates between the forced parasite stages of Trophont or the free form of Tomont (Jalali and Barzegar, 2006; Roberts, 2012; Straus and Meinelt, 2009). Trophont is the infectious stage of the parasite characterized by the parasites' free life. They readily invade their hosts like fish. After attaching to the body of the fish, it begins to grow and change to a more complete stage of Trophont (Fig 4, 5, 6, 7, 8, 9). Trophont will fade away if it cannot find a host within four days. The parasite *I. multifiliis* is almost spindle-

shaped, ciliated, with a crescent-shaped nucleus. Trophont changes to Tomont after final growth, leaving the host (Fig 3). Light is an effective factor in parasitic invasion of the host (Abdi, 2006; Buchmann *et al.*, 2003; Burkart *et al.*, 1990; Lahnsteiner and Weismann, 2007). Considering its complex life cycle, the parasite is a significant source of pathogenesis (Fig 6) affecting fins, skins, and gills of fish. It also causes hyperplasia of gill tissue, excessive mucus secretion, gill filaments adhesion, impaired respiratory system, resulting finally to fish death (Abdi, 2006; Jalali, 1998; Jalali and Barzegar 2006; Roberts, 2012; Sahandi *et al.*, 2012). Today, there are several methods for controlling and treating Ichthyophthiriasis using different chemicals (Jalali, 1998; Roberts, 2012). A less commonly used treatment is the use of calcium oxide (Cao) and sodium chloride (NaCl) to control and treat the protozoan. If calcium oxide is applied for treatment, the hardness and pH of water should remain unaffected, with the pH not exceeding 8 because the hard range is between 10 and 100 mg L<sup>-1</sup> in health, maintaining osmotic balance and recycling blood electrolytes that are excreted through the urine is vital for freshwater fish. (Abdi, 2006; Lahnsteiner and Weismann, 2007). Currently, all fish species, especially ornamental fish, are susceptible to such parasitic infestation which could induce severe economic losses and damage to fish farms each year. This research was conducted with the aim of selecting a substance that could have a good effect on Ichthyophthiriasis, entailing no environmentally destructive impacts.



**Figure 2.** Percentage of the effects of two drugs, calcium oxide and sodium chloride, on parasite Ich in the skin.



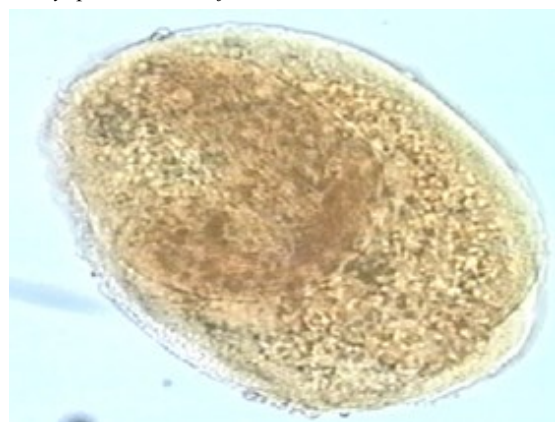
**Figure 3.** Percentage of the effects of two drugs, calcium oxide and sodium chloride, on parasite Ich in the fin.



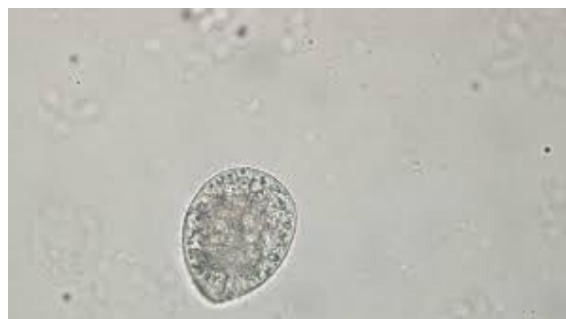**Figure 4.** Sample of goldfish infected with the *Ichthyophthirius multifiliis*.



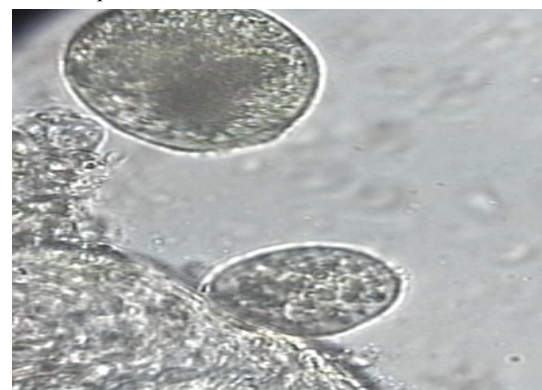
**Figure 5.** A sample of goldfish infected with white spots in this experiment.



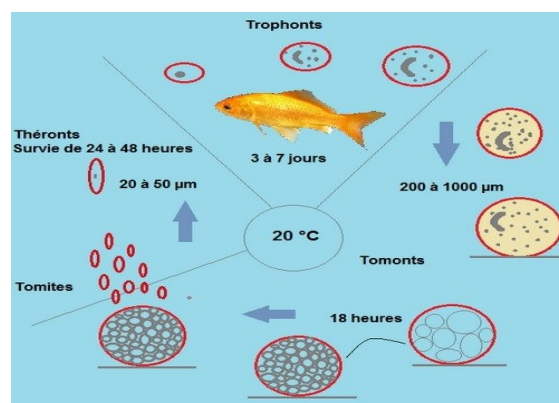
**Figure 6.** Trophont sample isolated from goldfish gill in this experiment.



**Figure 7.** Trophont sample isolated from goldfish water in this experiment.



**Figure 8.** Theront sample isolated from goldfish skin in this experiment.



**Figure 9.** The life cycle and duration of larval deformation in *Ichthyophthirius multifiliis*.

## Materials and Methods

The research was conducted from 22 June to 21 August 2019 at the Guilan Agricultural Research and Training Center (Mirzakoochakkhan Fisheries Training Center) in Rasht, Guilan Province. Seven aquaria were selected in two groups of three with a control group. ( $2 \times 1 \times 1$  m,  $2 \text{ m}^3$ ). In each aquarium, 25 gold fish (*Carassius auratus*, 20-30 g) were placed. All of the goldfish in the 7 aquaria were infected with Ich protozoan. Then wet slides were prepared to ensure that the fish were infected with *I. multifiliis*. Three treatments were performed using calcium oxide with therapeutic values of 13, 14 and 15  $\text{mg L}^{-1}$  with an interval of 72 h. Another three treatments were performed with sodium chloride with values of 1500, 2000, and 2500  $\text{mg L}^{-1}$  with an interval of 72 h as a permanent bath and a control group without treatment. The biological conditions of the fish were considered normal in terms of temperature between 25-28 °C, pH between 7 and 8 and water hardness between 100-70  $\text{mg L}^{-1}$ . In the first treatment the experimental group one, calcium oxide was used at a dose of 13  $\text{mg L}^{-1}$ . 24, 48 and 72 h after the first treatment, aquarium fish No. 1 were tested for the effect of the drug on parasite Ich. From the first treatment fish, 10 pieces were randomly sampled. After transferring the fish to the laboratory, wet slides were prepared from different parts of the body, such as skin, fins and gills, so that the parasites could be observed and counted under a microscope. In aquariums No. 2 and 3 of the first group,

$\text{CaO}$  14  $\text{mg L}^{-1}$  and  $\text{CaO}$  15  $\text{mg L}^{-1}$  were administered within 24, 48 and 72 h. The fish in these two aquariums were tested as in the first treatment. In the second group experiment, NaCl 1500  $\text{mg L}^{-1}$  was used in Aquarium No. 4. After 24, 48 and 72 h of the first treatment, 10 pieces were randomly sampled and tested to ensure the effect of the drug on Ich parasites. Following transferring the fish to the laboratory, wet slides were prepared from different parts of the body, including skin, fins and gills, so that the parasites could be observed and counted under a microscope. In aquariums No. 5 and 6 of this group, sodium chloride drug was used in 2000 and 2500  $\text{mg L}^{-1}$  doses with 24, 48 and 72 h intervals. The fish in these two aquariums were randomly sampled and tested as in the first treatment of this group. In order to make sure the drug effects on parasites throughout the experiment, samples were taken from 6 aquaria in two groups, No. 1 and 2. Samples of tissues from different parts of fish skin, fins and wet gills were prepared daily. The parasites count per unit area of the microscope was conducted using a lens grade 10. In this study, upon examining normality of the data, Kolmogorov-Smirnov test and one-way analysis of variance were used at the level of 0.5%, to compare the effectiveness of the two drugs. The data analysis was carried out through Duncan's discriminate test to compare the treatments with each other along with further analysis of data using SPSS20 statistical software. The study used a Nikon microscope with magnifications of 10x, 40x and 100x.

## Results

The results showed that Cao15 had the highest effect ( $p < 0.05$ ) on fish gills leaving the least parasite number in this area ( $4.17 \pm 2.48$ ). Also, Cao 15 and NaCl 2500 mg L<sup>-1</sup> had similar effects on the parasite in the

gill area ( $P > 0.05$ ). The lowest drug impact on Ich in the gills was related to sodium chloride at a dose of 1500 mg L<sup>-1</sup> (Table 1). On the other hand, Figure 1 confirms the above results.

**Table 1.** Statistical comparison of the effects of calcium oxide and sodium chloride on Ich parasite

		Mean	Std. Deviation	Std. Error	Minimum	Maximum
Gill	cao13	30.33 <sup>b</sup>	9.83	4.01	15.00	40.00
	cao14	13.67 <sup>c</sup>	4.27	1.74	8.00	20.00
	cao15	4.17 <sup>d</sup>	2.48	1.01	0.00	7.00
	NaCl 1500	49.17 <sup>a</sup>	11.70	4.78	34.00	60.00
	NaCl 2000	28.50 <sup>b</sup>	8.89	3.63	15.00	41.00
	NaCl 2500	19.00 <sup>c</sup>	5.59	2.28	11.00	26.00
Skin	cao13	23.50 <sup>b</sup>	6.98	2.85	12.00	31.00
	cao14	8.67 <sup>d</sup>	2.58	1.05	5.00	12.00
	cao15	1.83 <sup>d</sup>	2.40	0.98	0.00	6.00
	NaCl 1500	37.50 <sup>a</sup>	9.14	3.73	25.00	51.00
	NaCl 2000	25.00 <sup>b</sup>	8.17	3.34	12.00	35.00
	NaCl 2500	17.00 <sup>c</sup>	3.46	1.41	12.00	21.00
Fin	cao13	15.83 <sup>c</sup>	5.38	2.20	8.00	20.00
	cao14	10.50 <sup>c</sup>	4.23	1.73	4.00	17.00
	cao15	2.50 <sup>d</sup>	1.87	0.76	0.00	5.00
	NaCl 1500	39.33 <sup>a</sup>	10.25	4.18	29.00	54.00
	NaCl 2000	27.00 <sup>b</sup>	7.95	3.25	16.00	36.00
	NaCl 2500	17.00 <sup>c</sup>	5.44	2.22	10.00	24.00

The varying letters of each tissue in the columns refer to significant difference.

As it can be seen, by using calcium oxide, fish showed the lowest percentage of contamination (2.88%). Calcium oxide at a dose of 15 mg L<sup>-1</sup> showed the greatest effect on the control of Ich in the skin ( $2.40 \pm 0.98$ ,  $p < 0.05$ ). Cao13 mg L<sup>-1</sup> and NaCl 2500 mg L<sup>-1</sup> depicted similar effects on the skin ( $p > 0.05$ ). Sodium chloride (NaCl1500 mg L<sup>-1</sup>) showed the lowest effect on the skin parasites (Table 1). Figure 2 shows that fish with calcium oxide had the lowest percentage of contamination (1.62%). The results showed that, Cao15 mg L<sup>-1</sup> had the highest inhibitory

effect ( $p < 0.05$ ) on Ich in the fin area ( $2.50 \pm 1.87$ ). Cao13 mg L<sup>-1</sup> and Cao13 mg L<sup>-1</sup> along with NaCl 1500 mg L<sup>-1</sup> showed similar effects on parasite control ( $p > 0.05$ ). The use of NaCl1500 mg L<sup>-1</sup> had the lowest effect on parasite control (Table 1). Figure 3 showed that fish with calcium oxide at a dose of 15 mg L<sup>-1</sup> have the lowest percentage of contamination (2.23%).

## Discussion

Many parasites at larval stage may live freely in the water for a long time and ultimately find

their way in fishes. Providing water free of pathogens should be one of the most important principles of a fish farmer's health management scheme. All free forms of protozoan parasites, which are rampant in farmed fish population throughout the country, are transmitted to fish farms by water. There are several ways to eliminate or control parasitic diseases, such as using filters to supply water devoid of parasitic agents, providing healthy food based on hygienic principles, decontamination of pools and farming equipment, disinfecting fish, as well as controlling carriers. *I. multifiliis* is the most dangerous parasitic protozoan of freshwater fish, especially in goldfish pools. One of the main causes of such disease outbreak is high density in red fish farms (Lahnsteiner and Weismann, 2007; Osman *et al.*, 2009; Sahandi *et al.*, 2012; Sharma *et al.*, 2012; Traxler *et al.*, 1998). The free-form of the active *I. multifiliis* parasites called Theront, can live in pools for up to 4 days without hosts. During this time, Theronts can easily reach the host and end up in various fish complications including hyperplasia, excessive mucus secretion, gill adhesions, respiratory disorders, irritability and anxiety, loss of appetite, weight loss, emaciation and mortalities among juveniles (Lahnsteiner and Weismann, 2007; Sharma *et al.*, 2012; Straus and Meinelt, 2009; Woo, 2006; Xu and Klesius, 2004). The study probed into elimination ways of parasite's life cycle, including the parasite's free and infectious form. Theront, a more advanced stage of the trophont, and the parasitic stage called Thomont, reside on algae, rocks,

bedrock, and aquariums. Treatment and control of white spot disease in earthen pools is difficult because the cystic form of the parasite protects itself by creating a cover (Rintamäki-Kinnunen *et al.*, 2005). The size of the pool and the speed of its water flow are very crucial in reducing the severity of parasite infection (Bodensteiner *et al.*, 2000). Malachite green is useful in controlling white spot disease, but it is not advised for usage due to the long-term persistence of the drug in fish and its being carcinogenic. Chloramine-T and potassium permanganate also have a destructive impact on fish gill tissues (Buckmann, 2003). Formalin is one of the most widely used chemical drug for the treatment of white spot disease in fish farms, but there are debates on its effectiveness because a part from its harmful impacts on gill tissues, it has also negative effects on the environment (Tieman and Goodwin, 2001). Garlic and sodium bicarbonate extracts were used in Denmark and Spain on *I. multifiliis* but were of no effect (Tojo *et al.*, 1994; Buchmann *et al.*, 2003). Lan Steiner and Wisman (2007) tested the effects of sodium chloride and formalin on salmon and carp parasite, showing that formalin was effective on parasite but sodium chloride was not effective in treating fish. Natalia *et al.* (2017) reported hydrogen peroxide and chlorine dioxide in bath therapy could be up to 90% effective in inhibiting Ich, which is consistent with the findings of this study. Psoralidin can eliminate theronts at 0.8 mg L<sup>-1</sup> during 4 h challenge; and lay off rehabilitation of *I. multifiliis* post 6 h introduction of protomonts to 0.9 mg L<sup>-1</sup>. In



*vivo* test exhibited that 5 h exposure of contaminated fish to 2.5 mg L<sup>-1</sup> of Psoralidin significantly decreased the value of theronts released from tomonts (Song, *et al.* 2015). A concentration of 82.54 ppm of the commercial compound as LC<sub>50</sub>, 96h of H<sub>2</sub>O<sub>2</sub> and 38.4 ppm compound for ClO<sub>2</sub> was reported. At this concentration, hydrogen peroxide could kill 100% of theronts within 1h at 25 ppm. At the end of the fourth day of experiment, 98% of the animals were killed by ichthyophthiriasis. No effectiveness was observed against the parasite. Noor *et al.* (2015) showed that although onion extract is effective in reducing parasite one, it cannot completely control it, which has effects similar to sodium chloride in this experiment. Bookman *et al.* (2003) reported that bath therapy with onion extract and sodium percarbonate was not effective in controlling Ich, which again agrees with the findings of this study.

Calcium oxide and sodium chloride are among the substances used in various stages of freshwater fish farming as disinfectants (Lahnsteiner and Weismann, 2007; Noga, 2010; Osman *et al.*, 2009; Tieman and Goodwin, 2001; Xu and Klesius, 2004). Sodium percarbonate is an environmental friendly complex assessed against different stages of *I. multifiliis* (Buchmann *et al.*, 2003; Heinecke and Buchmann, 2009) showing a dosage of 12.5 mg L<sup>-1</sup> for 3h and 62.5 mg L<sup>-1</sup> for 90 min successfully eliminate in *I. multifiliis* theronts (Buchmann *et al.*, 2003), while tomonts showed more resistance to it (Heinecke and Buchmann, 2009). In the first experimental group (Table 1), the effect of

Cao15 mg L<sup>-1</sup> was significantly different ( $p < 0.05$ ) compared to NaCl 2500 mg L<sup>-1</sup> on Ich parasite ( $4.17 \pm 2.48$ ). In the second group, sodium chloride was used as a permanent bath with three different doses- 1500, 2000 and 2500 mg L<sup>-1</sup>. Although an increased dose of this drug resulted in lower number of parasites, it failed to completely eradicate infectious parasitic Ich that was consistent with the other reports (Bookman *et al.*, 2003; Tojo *et al.*, 1994; Lan Steiner *et al.*, 2007). This study also showed the higher inhibitory effect of calcium oxide (Cao) in reducing Ich quantity in all stages of the experiment, compared to sodium chloride in the gills (2.88%), skin (1.62%) and fins (2.23%) was shown in Fig. 1, 2 and 3. Although an increased dose of this drug resulted in lower number of parasites, it failed to completely eradicate infectious parasitic Ich. However, the study was an attempt to compare and contrast the effect of these two compounds on *I. multifiliis*. The results obtained concerning calcium oxide and sodium chloride are consistent with those of earlier reports (Alam *et al.*, 2014; Buchmann *et al.*, 2003; Roberts, 2012; Xu *et al.*, 2002; Zhang *et al.*, 2009). It was also found in the study that calcium oxide could be effective in wiping out the pathogenic Ich parasite on ornamental fish and might be used on other farmed fish without having a detrimental effect on the environment.

## Acknowledgment

We would like to thank the esteemed director of Navid Reproduction and Development Center and Mr. Kazemi, who helped us in this research.

## Conflicts of interest

None of the authors has any conflicts of interest to declare.

## References

Abdi, K., 2006. In formation and Application Aquatic Animals Pharmaceuticals, Publishers Daneshnegar pub, Daneshnegar, Tehran, Iran, 1Ed.p:258. (In Persian).

Alam, M.N., Ahmed G. U. and Chowdhury, M.B.R., 2014. Performance of herbal extracts on diseased fish. *Bangladesh Journal of Veterinary Medicine*, 12 (2), 225-230.

Bodensteiner, L.R., Sheehan, R.J., Wills P.S., Brandenburg, A.M. and Lewis W.M., 2000. Flowing water: an effective treatment for ichthyophthiriasis. *Journal of Aquatic Animal Health*, 12, 209–219.

Buchmann, K., Bresciani, J. and Larsen. A.H., 2003. Effects of sodium percarbonate and garlic extract on *Ichthyophthirius multifiliis* theronts and tomocysts: in vitro experiments. *North American Journal of Aquaculture*, 65, 21-24.

Burkart, M.A., Clark, T.G. and Dickerson, H.W., 1990. Immunization of channel catfish, *Ictalurus punctatus* Rafinesque against *Ichthyophthirius multifiliis* (Fouquet): killed versus live vaccine. *Journal of Fish Diseases*, 13, 401-410.

Christoffersen, T.B., Kania, P.W., Gersdorff Jorgensen L. and Buchmann K., 2017.

Zebrafish *Danio rerio* as a model to study the immune response against infection with *Ichthyophthirius multifiliis*. *Journal of Fish Diseases*, 40, 847–852.

Heinecke, R.D. and Buchmann K., 2009. Control of *Ichthyophthirius multifiliis* using a combination of water filtration and sodium percarbonate: dose-response studies. *Aquaculture*, 288, 32-35.

Jalali, B. 1998. Parasites and parasitic diseases of Iranian freshwater fish, Iranian Department of Aquaculture, Iran Fisheries Publications, Tehran, Iran 1st Ed.p:155-167.

Jalali, B. and Barzegar, M., 2006. Fish parasites in Zarivar Lake. *Journal of Agricultural Science and Technology*, 8, 47-58.

Lahnsteiner, F. and Weismann, T. 2007. Treatment of Ichthyophthiriasis in rainbow trout and common carp with common and alternative therapeutics. *Journal of Aquatic Animal Health*, 19, 186-194.

Natalia, D.A., Marchior, C., Fabiano, M., Maurício, S., Martins, S., Amaral, H., Bruno, J., Corrêa, D.A. and Silva, C. 2017. Hydrogen peroxide and chlorine dioxide against parasite *Ichthyophthirius multifiliis* (Protozoa, Ciliophora) in jundiá fingerlings, *Parasitology*, 47 (12).

Noga, E.J., 2010. Fish disease: diagnosis and treatment, Iowa State university Press, USA, 2 Ed. P: 95-97.



- Noor El-Deen, A.I., Abd El Hady, O.K., Kenawy, A.M. and Mona, S.Z., 2015. Study of the Prevailing External parasitic diseases in cultured freshwater tilapia (*Oreochromis niloticus*) Egypt. *Life Science Journal*, 12(8), 30-37.
- Osman, H.A.M., Monier, M.M., Abd El Ghany, O.A., Ibrahim, T.G. and Ismail, M.M., 2009. Protection of goldfish (*Carassius auratus*) against *Ichthyophthirius multifiliis* by immunization with live theronts, trophonts and sonicated trophonts. *Global Veterinaria*, 3(4), 329-334.
- Rintamäki-Kinnunen, P., Rahkonen, M., Mannermaa-Keränen, A.L., Suomalainen, L.R., Mykrä, H. and Valtonen, E.T., 2005. Treatment of ichthyophthiriasis after malachite green. I. Concrete tanks at salmonid farms. *Diseases of aquatic organisms*, 64(1), 69-76.
- Roberts, R.J. 2012. Fish Pathology, Bailliere Tindall, London. England. 4th Ed. P: 270.
- Sahandi, J., Kanani, H.G. and Asgarabad, F.R. 2012. Influence of garlic (*Allium Sativum*) and mother worth (*Matricaria chamomilla*) Extract effects on *Ichthyophthirius multifiliis* Parasite Treatment in Sail Fin Molly (*Poecilia latipinna*) Ornamental Fish. *Global Veterinaria*, 9 (3), 362–366.
- Sharma, M., Srivastav A.B., Sahni, Y.P. and Pandey, G., 2012. Overviews of the treatment and control of common fish diseases. *International Research Journal of Pharmaceuticals*, 3(7), 123-127.
- Song, K., Ling, F., Huang, A., Dong, W., Liu, G., Jiang, C. and Wang, G., 2015. In vitro and in vivo assessment of the effect of antiprotozoal compounds isolated from *Psoralea corylifolia* against *Ichthyophthirius multifiliis* in fish. *International Journal for Parasitology: Drugs and Drug Resistance*, 5(2), 58-64.
- Straus, D.L. and Meinelt, T., 2009 Acute toxicity of peracetic acid (PAA) formulations to *Ichthyophthirius multifiliis*. *Parasitology Research*, 104, 1237-1241.
- Tieman, D.M. and Goodwin, A.E., 2001. Treatments for ich infestations in channel catfish evaluated under static and flow through water conditions. *North American journal of aquaculture*, 63, 293–299.
- Traxler, G.S., Richard, J. and McDonald, T.E. 1998. *Ichthyophthirius multifiliis* (Ich) epizootics in spawning sockeyes salmon in British Columbia, *Canadian Journal of aquatic animal health*, 10, 143-151.
- Woo, P.T., Leatherland, J.F. and Bruno, D.W., 2006. *Fish diseases and disorders* (Vol. 3). CABI.
- Xu, D.H. and Klesius, P.H., 2004. Two-year study on the infectivity of *Ichthyophthirius multifiliis* in channel catfish *Ictalurus punctatus*. *Diseases of Aquatic Organisms*, 59(2), 131-134.
- Xu, D., P.H., Klesius, C.A. and Shoemaker J. J., 2002. *Ichthyophthirius multifiliis* in Channel Catfish in Vitro. *Journal of Aquatic Animal Health*, 12, 290-296.

Zhang, Q., Chen, D. and Liu, Q., 2009.  
Protective immunity of goldfish against  
*Ichthyophthirius multifiliis* infection Induced  
by different trophont vac-Cine preparations.  
*Journal of World Aquaculture Society*, 40,  
561–566.