

Short communication

Ectoparasite fauna of goldfish (*Carassius auratus*) in north of Iran

P Shohreh¹, S Mehdizadeh Mood², M Ghadam¹, Sh Shafiei¹, A Taheri- Mirghaed¹ and A Babaalian¹

¹Faculty of Veterinary Medicine, University of Tehran, Tehran, Iran

²Faculty of Veterinary Medicine, Semnan University, Semnan, Iran

Received: February 2014

Accepted: July 2014

Abstract

The present study was carried out to survey ectoparasite fauna of gold fish (*Carassius auratus*) in north of Iran (Mazandaran province). A total of 200 samples were obtained from 10 ornamental fish supply centers and transferred alive to the laboratory. In this study, the following ectoparasites were isolated: *Ichthyophthirius multifiliis*, *Trichodina* spp., *Gyrodactylus* spp., *Dactylogyrus vastator*, *Dactylogyrus baueri* and *Argulus coregoni*. The results revealed that 28.5% of sampled goldfish were infested with ectoparasites. The frequency of protozoan infestations were 15% (9% *I. multifiliis* and 6% *Trichodina* spp.), the frequency of monogenean ectoparasite was 12.5% (5% *Gyrodactylus* spp., 5% *D. vastator* and 2.5% *D. baueri*) and that of crustaceans (*A. coregoni*) was 1%. The most frequently reported infestation was due to *I. multifiliis* causative agent of white spot disease. Enhancing the health management through improving water quality and bio-security is the most effective way to prevent the parasite infestations.

Keywords: infestation, goldfish, protozoan, monogenean.

Introduction

Ornamental fish keeping is one of the most common hobbies in the world and the health of this aquatic species has become highly important. Mazandaran

province is one of the important areas of this industry and of course, one of the most popular pet animal species is goldfish (*Carassius auratus*). There are different reports on the occurrence of ectoparasite infestation in this ornamental fish species. Such infestation can cause severe skin damage, eroded fins, increased morbidity and susceptibility to secondary infections (Pike 1989). Furthermore, affected fish respiratory function can be drastically impaired because of hyperplasia, degeneration and necrosis of the gills. Ebrahimzadeh Mousavi (2003) has reported different ectoparasites in goldfish. Mehdizadeh Mood (2009) isolated enormous new range of ectoparasites in 10 species of imported ornamental fish and declared that the most infected species was gold fish. Knowledge of the parasites, their hosts and their prevalence is an essential prerequisite of preventative procedures for the parasite problem in aquaculture. The present survey was performed to determine the ectoparasite fauna of gold fish in order to provide further necessary preventive and control measurements in this commercial species.

Materials and Methods

Two hundred samples of gold fish were sampled randomly from 10 ornamental fish supply centers in Mazandaran province, Iran from April 2009 to March 2010. Specimens were transferred alive to an aquatic laboratory in Amol (Mazandaran, Iran). First, the fish were examined macroscopically for their health and physical characteristics, presence or absence of any abnormal clinical signs and cysts or arthropods. Then, they were examined using stereo microscope. Having observed different parts of fish body surface, the *Argulus* were isolated by forceps and inspected alive as fixed in 70% ethyl alcohol un-

Correspondence P Shohreh, Department of Aquatic Animal Health. Faculty of Veterinary Medicine, University of Tehran, Tehran, Iran (e-mail: Poulin_shohreh@ut.ac.ir)

der light microscope. After that, wet mount smears of skin, fins and gills were prepared and observed carefully under the light microscope. Parasites were identified according to the key detections described by Bykhovskaya-Pavlovskaya, Gusev, Dubinina, Izyumova, Smirnova, Sokolovskaya, Shtein, Shulman & Epstein (1964). Argulus species was identified using morphological keys including length of body, posterior lobes of carapace, urosome and posterior incisure of urosome and *A. coregoni* was characterized by its extremely sharp lobes, not having urosome marginal spines and a whole body length of more than 10 mm. Finally, the prevalence and frequency of each parasite species were statistically estimated.

Results

The result showed that from a total of 200 investigated goldfish, 57 specimens (28.5%) were infested with ectoparasites. Based on the intensity of infestation, features like faintness and erratic swimming were observed in infested goldfish. Clinical signs also included cutaneous bleeding, fin bleeding, scale loss, fin rot, skin wounds, and superficial mucus expansion. Through parasitic examination the following species were identified: *Ichthyophthirius multifiliis*, *Trichodina* spp., *Gyrodactylus* spp., *Dactylogyrus vastator*, *Dactylogyrus baueri* and *Argulus coregoni* (Fig. 1). Table 2 shows the number of infested fish and the prevalence of infestation in the infested fish.

The results showed that the frequency of protozoan infestation was 15% (9% *I. multifiliis* and 6% *Trichodina* spp.), the frequency of monogenean parasite was 12.5 % (5% *Gyrodactylus* spp, 5% *D. vastator* and 2.5% *D. baueri*) and that of crustacean (*A. coregoni*) was 1%. The most frequently reported infestation was due to *I. multifiliis*.

Discussion

Fish are continuously exposed to stressful procedures in rearing facilities (e.g. poor water quality, transport, overhandling and overcrowding) (Barton & Iwama 1991; Petrescu-Mag, Oroian & Petres-

Table 1 Infestation value of Ectoparasites on the infested goldfish

Ectoparasite species	Number of infested fish	Prevalence of infestation (%)
<i>I. multifiliis</i>	18	31.58%
<i>Trichodina</i> spp.	12	21.05%
<i>Gyrodactylus</i> spp.	10	17.54%
<i>D. vastator</i>	10	17.54%
<i>D. baueri</i>	5	8.78%
<i>A. coregoni</i>	2	3.51%
Total	57	100%

cu-Mag 2007). External parasites are the most common parasites encountered in aquatic animals raised in both ponds and aquaria (MacMillan 1991). Ectoparasite infestations can cause severe skin damage, eroded fins, increased morbidity and susceptibility to secondary infections (Pike 1989). Furthermore, in affected fish respiratory function can be drastically impaired because of hyperplasia, degeneration and necrosis of the gills.

The present study revealed that the overall frequency of infestation was 28.5% and demonstrated the increasing concern of parasitic infestation in gold fish in the Mazandaran province of Iran. The most frequently reported infestation was due to *I. multifiliis* (9%). *I. multifiliis* is a causative agent of white spot disease causing a high contagious infection and spreads rapidly from one fish to another. Due to the parasites life cycle, only the free-swimming stage of the parasite is susceptible to chemical substances. Neither the trophonts under the epithelium nor the tomont cysts can be killed. However, a repeated treatment is able to omit the juvenile tomites. Both Ebrahimzadeh Mousavi (2003) and Mehdizadeh Mood (2009) reported *I. multifiliis* in goldfish in Iran. Careful management (such as quarantine and multiple treatments) is necessary, and this can minimize the economic losses. *Trichodina* was another protozoan parasite that was isolated in this study. These obligatory ectoparasites can survive without fish for hours and can temporarily be supported by several species of hosts other than fish (Thilakaratne, Rajapaksha, Hewakopara, Rajapakse & Faizal 2003). This may explain their widespread of occurrence and prevalence. The frequency of monogenean was 12.5% (5% *Gyrodactylus* spp., 5% *D. vastator* and

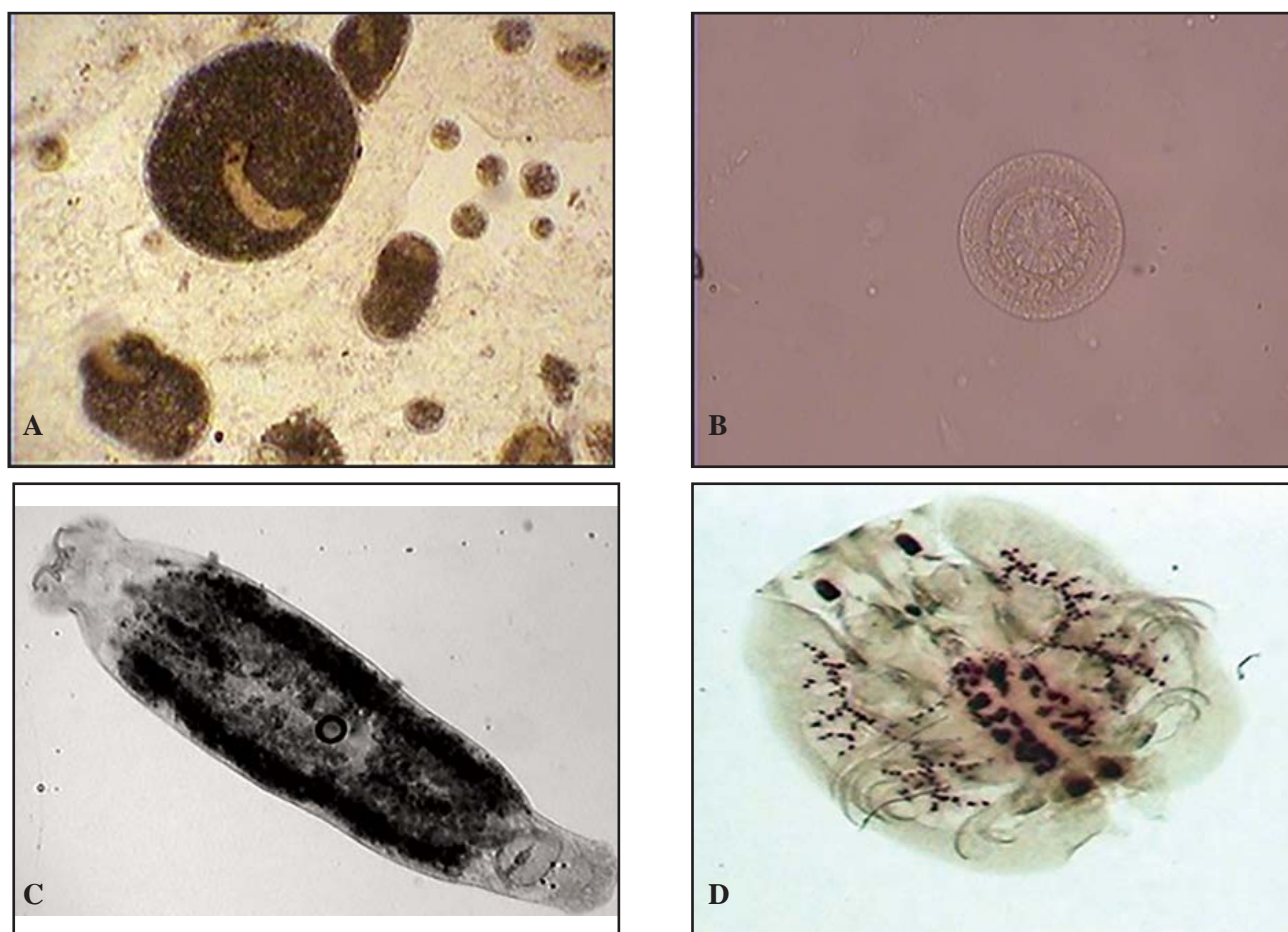


Figure 1 Isolated ectoparasites A: *I. multifillis* X=100, B: *Trichodina* spp. X=400, C: *D. vastator* X=100, D: *Argulus coregoni*. X=400.

2.5% *D. baueri*). Ebrahimzadeh Mousavi (2003) had isolated *Dactylogyrus xtensus* but we did not. Mehdizadeh Mood (2009) isolated the same species of *Dactylogyrus* in gold fish. Prevention of monogenean infestations by quarantine practices is preferable to treating the parasites after they have become established in a system. Members of the genus *Dactylogyrus* are egg layers. The eggs can be resilient to chemical treatment, therefore multiple treatments (1 dose per week) are appropriate to control this group of organisms (Reed, Francis-Floyd & Klinger 2005). In Iran, different species of *Argulus* were reported from different hosts (Shoemaker, Evans & Klesius 2000; Petrescu-Mag *et al.* 2007; Mehdizadeh Mood 2009). The frequency of *A. coregoni* infestation in this survey was 1%. Also, Ebrahimzadeh Mousavi, Behtash, Rostami-Bashman, Mirzargar, Shayan & Rahmati-holasoo (2011) reported the *A. coregoni* as the least frequent *Argulus* species in his study. Pre-disposing stressors including over handling, over-crowding of the fish, poor quarantine conditions,

poor sanitation practices and poor bio-security can accelerate the disease outbreaks (Shoemaker *et al.* 2000), therefore enhancing the health management through improving water quality and bio-security of fish farms is the most effective way to prevent the parasite infestation. Control of fish parasites requires knowledge of the parasites of each region, their hosts and their prevalence, therefore periodic parasitological examination can contribute to the control of fish parasites and their economic losses.

References

- Barton B.A. & Iwama G.K. (1991) Physiological changes in fish from stress in aquaculture with emphasis on the response and effects of corticosteroids. *Annual Review of Fish Diseases* 1, 3–26.
- Bykhovskaya-Pavlovskaya I.E., Gusev A.V., Dubinina M.N., Izyumova N.A., Smirnova T.S., Sokolovskaya I.L., Shtein G.A., Shulman S.S. & Epstein V.M. (1964) *Key to*

Parasites of Freshwater Fish of the USSR. Publishing House AkademiiNauk, Leningrad.

EbrahimzadehMousavi H.A. (2003) Parasites of ornamental fish in Iran. *Bulletin of the European Association of Fish Pathologists* **23**, 279-300.

EbrahimzadehMousavi H.A., Behtash F., Rostami-Bashman M., Mirzargar S., Shayan P. & Rahmati-holasoo H. (2011) *Study of Argulus spp. infestation rate in Goldfish, Carassius auratus* (Linnaeus, 1758) in Iran. *HVM Bioflux* **3**, 198-204.

MacMillan J.R. (1991) Biological factors impinging upon control of external protozoan fishparasites. *Annual Review of Fish Diseases* **1**, 119-131.

Mehdzadeh Mood S. (2009) *Study of ectoparasite infestation of 10 common imported freshwater ornamental fish species*. PhD Thesis, University of Tehran, Tehran, Iran.

Petrescu-Mag I.V., Oroian I., Petrescu-Mag R.M. (2007) *The cold-water tolerance in Trematomus bernacchii* (Boulenger 1902) and the heat shock proteins implications. *ELBA Bioflux Pilot* (a), 11-14.

Pike A.W. (1989) Sea lice-major pathogens of farmed Atlantic salmon. *Parasitology Today* **5**, 291–297.

Reed P., Francis-Floyd R. & Klinger R. (2005) Monogenean Parasites of Fish. *EDIS* **7**, 1-8.

Shoemaker C.A., Evans J.J. & Klesius P.H. (2000) Density and dose: factors affect in mortality of *Streptococcus iniae* infected tilapia (*Oreochromis niloticus*). *Aquaculture* **188**, 229–235.

Thilakaratne I.D., Rajapaksha G., Hewakopara A., Rajapakse R.P. & Faizal A.C. (2003) Parasitic infections in freshwater ornamental fish in Sri Lanka. *Diseases of Aquatic Organisms* **54**, 157–162.

بررسی آلودگی انگلی ماهی طلایی (*Carassius auratus*) در استان مازندران

پولین شهره^{۱*}، سارا مهدیزاده موعود^۲، معصومه قدم^۱، شفیق شفیعی^۱، علی طاهری میرقائد^۱، علیرضا باباعلیان امیری^۱

۱ گروه بهداشت و بیماریهای آبزیان، دانشکده دامپزشکی دانشگاه تهران، تهران، ایران

۲ دانشکده دامپزشکی دانشگاه سمنان، سمنان، ایران

چکیده

این مطالعه به منظور بررسی شیوع انگل‌های خارجی ماهی طلایی واقع در استان مازندران در بازه زمانی یک ساله صورت گرفت. بدین منظور تعداد ۲۰۰ ماهی خریداری شده از ۱۰ مرکز فروش ماهیان زینتی بصورت زنده به آزمایشگاه منتقل گردیده و از نظر انگل شناسی مورد بررسی قرار گرفتند. در مجموع ۲۸/۵٪ از نمونه‌ها آلوده به انگل بودند و انگل‌های خارجی داکتیلوژیروس و استاتور، داکتیلوژیروس باثری، تریکودینا، ژیروداکتیلوس، آرگولوس کورگونی و ایکتیوفتیریوس مولتی فیلیس در نمونه‌های گرفته شده مشاهده شد. مقدار فراوانی آلودگی با تک یاخته‌ها ۱۵٪ بود که ۹٪ مربوط به ایکتیوفتیریوس مولتی فیلیس و ۶٪ مربوط به تریکودینا بود. همچنین فراوانی انگل‌های مونوژن ۱۲/۵٪ گزارش گردید که ۵٪ مربوط به انگل ژیروداکتیلوس، ۵٪ مربوط به انگل داکتیلوژیروس و استاتور و ۲/۵٪ مربوط به داکتیلوژیروس باثری می‌باشد. براساس نتایج بالاترین و کمترین میزان فراوانی انگل‌های مشاهده شده به ترتیب مربوط به انگل ایکتیوفتیریوس مولتی فیلیس عامل بیماری لکه سفید و انگل آرگولوس کورگونی (۱٪) بود. تقویت مدیریت بهداشتی از طریق بهبود کیفیت آب و امنیت زیستی از موثرترین روش‌ها به منظور جلوگیری از هجوم انگل می‌باشد.

واژه‌های کلیدی: ماهی طلایی، تک یاخته، مونوژن، آلودگی انگلی.

*نویسنده مسئول: Poulin_shohreh@ut.ac.ir