

Research Article

Identification of *Chalcalburnus chalcoides* internal parasites in Sefidrood River, Guilan, Iran

M. Rahanandeh^{1*}, B. Tizkar¹, M. Abedi²

¹Guilan Agricultural and Natural Resources Research and Education Center, Agricultural Research, Education and Extension Organization (AREEO), Rasht, Iran

²Institute of Agricultural Education and Extension, Agricultural Research, Education and Extension Organization (AREEO), Tehran, Iran

Received: August 2021

Accepted: November 2021

Abstract

During this research from April to August 2020, some 30 fish of *Chalcalburnus chalcoides* were caught from different parts of Sefidrood by cast nets. The fish were anesthetized using 25 mg/l of clove flower extract. In order to identify the parasites, blood, eyes, various internal organs were sampled. All of the isolated parasites were stained and clarified using Hematoxylin and Eosin stain and valid parasitology keys. Examination of internal parts of *Chalcalburnus chalcoides* revealed varying degrees of infestation by different parasitic species, including fish eyes infection by trematodes *Diplostomum spathaceum*, (infestation percentage 53.3%). Meanwhile, blood was affected mainly by *Trypanosome percae* (13.3%),

Cryptobia sp. (10%), abdominal cavity by *Eustrongylides excisus* (20%), *Clinostomum complanatum* (13.3%), anisakis larvae (23.3%), *Asymphylogora kubanicum* (46.6%), *Caryophylaelus laticeps* (13%), *Khavaia arminica* (76.6%), metacercaria plerocercoid *Ligula intestinalis* (13.3%), *Bothriocephalus gowkongensis* (20%), *Raphidascaris acus* (26%) and *Corynosoma caspicum* (30%). Almost all of the examined fish were found to have been infested by at least one or two parasite species. The new finding of this research is that isolation and identification of four parasites species namely as zoonosis *Clinostomum complanatum*, *Eustrongylides excisus*, *Ligula intestinalis* and Anisakis larvae are reported in this fish species for the first time.

*Corresponding author E-mail:
rahanandeh1340@gmail.com

Keywords: Guilan, Sefidrood River, parasites, *Chalcalburnus chalcoides*

Introduction

Chalcalburnus chalcoides is a cyprinid species with upper mouth and silver scales. The keel is scale less lying between pectoral and caudal fins (Abassi, *et al.*, 1999). Being an anadromous species, the fish migrate from the Caspian Sea to Sefidrood and Anzali lagoon to spawn which constitute the main habitat of *Chalcalburnus chalcoides* and its many subspecies (Asgari, 2009). The fish matures at 2-3 years of age and swim upstream to Sefidrood, during May - August. They mostly live on planktons, insect larvae and benthos. The body length and weight are, on average 18 cm and 45 grams respectively (Abassi, *et al.*, 1999). Sefidrood (white river) historically known as Amard (Arabani, 2001) is Iran's second longest river, formed by the intersection of two other rivers namely Gezelozan and Shahrud. In the investigations conducted as part of a comprehensive fisheries plan (1994-95), some 45 species and subspecies belonging to 36 genders and 17 families were identified in different areas of Sefidrood River as well as in the main branches of Gezelozan and Shahrood that flow into Sefidrood. Amongst these, Acetra and Beluga sturgeons, *Rutilus frisii kutum*, common carp, *Barbus brachycephalus caspius*, *Vimba vimba*, *alburnus chalcoides*, *Chalcalburnus chalcoides*, catfish (*Silurus glanis*), Tench (*Tinca tinca*) and of course, Cyprinids accounted for the bulk of migrating fish. Located in southern Caspian Sea region, Sefidrood is unique in that, it is a major destination for fish migration providing the

nursery ground for a number of commercially important caviar fish species such as Sturgeons and bony fish (Karimpour, *et al.*, 1992). The discharge of industrial wastewater, sewage from both urban and rural areas, agricultural run offs, introduction of chemicals such as nitrate, phosphate, pesticides and the sludge coming from slaughter houses have, all together, brought about devastating changes on the delicate natural ecosystem of Sefidrood. All these could, apart from total annihilation of aquatics and various life forms, entail severe economic complications for the livelihood of the local communities (Abassi, *et al.*, 1999; Arabani, 2001). The entry of such pollutants into the Caspian Sea has led to certain unpleasant consequences such as the red tides and phytoplankton blooms. Unfortunately, such unattended approaches toward the ecosystem have caused major destruction in Sefidrood basin resulting in the grim shift from its being an active ecosystem to an inactive one. In addition, these contaminated river waters have paved the way for fish harboring a number of viral, bacterial and fungal diseases. Due to its good quality flesh, *Chalcalburnus chalcoides* is very popular with high demand in the seafood market of northern Iran. Thus, the catch of such fishery stock becomes economically important during their natural propagation in spring (Rahanandeh, 2021). Since biological and/or ecological studies of such fish species in the aquatic ecosystem is a prerequisite for any conservation and stock rehabilitation effort.

This study might lead to better ecological knowledge on their food chain and shed more lights onto the fish diseases and parasitic infections within the ecosystems (Rahanandeh, 2021; Jalali, 1998; Kazanchev, 1981; Nikolski, 1969). There has been a decline in the fish stocks in recent years due mainly to the environmental pollutions. The objective of the present research is to gain a better understanding on the growing pace of environmental pollution disrupting the natural habitats and recruitment of this fish stock. It is also important to identify the various parasite species particularly parasitic zoonosis in such fish species since the fish has a noticeable share in the food consumption of the local inhabitants in the northern provinces of Iran. This might also effectively contribute to the preventive measures, via raising public awareness on zoonosis-induced diseases (Rahanandeh, 2021).

Materials and methods

The present research was conducted during (April-August 2020) included 30 pieces of *Chalcalburnus chalcoides* caught from different parts of Sefidrood by cast nets. The fish transferred alive, in aerated tank to the Mirzakoochak khan Fish Health laboratory Rasht. The fish were kept in aquarium under suitable temperature 25 °C, oxygen 5 mg / L and pH 7.5 condition. Each fish went under scrutiny for parasite detection individually via procedure set forth by Mulnar, 1992, Gussey, 1993a and Bychowsky, 1949. In order to sample the inner parts of the fish, they were

anesthetized using clove extract at a dose of 25 mg/l. The fish were blood sampled. Blood spread was prepared, then stained with Giemsa to identify parasites in the blood. The eyes dissected by scalpel and scissors from the eye sockets of anesthetized fish and then were placed into the 6% physiological serum. Upon removing the contents of fish eye lenses, the parasites introduced in culture plate containing the serum were collected using a pipette and then stained by H&E to carry out the morphological specification of parasites through the microscope. The fish were, next subjected to autopsy based on Roberts' method (2010). After autopsy, the dissected fish heart, kidneys, liver, swim bladder, and ovaries underwent close morphological examinations to check for any infestation of abdominal cavity. The digestive organs of the fish were completely removed from the abdominal cavity and put into 6% physiological serums. A syringe (2cc) containing 6% serums was used to pour the intestinal contents onto a special sieve whereby after washing the fish feces, the parasites could be isolated and identified. A scissor was, next used to cut through the guts in order to make isolation and identification of intestinal parasites such as nematodes and cystoids possible. Since intestinal trematodes constitute certain parasites within the guts, a mucus smear of the gut was also prepared. The identification of parasites involved clarification and staining of isolated parasites with H&E and the use of valid parasitology keys.

Results

The examination of the internal parts of 30 pieces of *Chalcalburnus chalcoides* during 5 months of sampling, 14 parasitic species were isolated and identified. The most important internal parasitic species detected from the eye: *Diplostomum spathaceum* parasite with 53.3% (Figure 1). Blood: *Trypanosoma percae* 13.3%, *Cryptobia* sp. 10% (Figure 2). The abdominal cavity: *Eustrongylides excisus* 20%, metacercariae *Clinostomum complanatum* 13.3%, followed by 10% infection of Anisakis larvae (Figure 3). Meanwhile the detected parasite forms isolated and detected from different intestinal parts showed (23.3% infestation) Anisakis larvae, *Asymphylogora kubanicum* 46.6%, *Caryophyllaeus laticeps* 13%, *Khavia*

Armenica 76.6%, Metacercariae *Plerocercoid ligula intisetinalis* 13.3%, *Bothriocephalus gowkongensis* 20%, *Raphidascaris acus* 26% and two *Acantocephalus pomfericus proferator* 20% and *Korinosoma caspicum* 30% (Figure 4). It was found that almost all (100%) of the examined fish were infected by at least one or two parasitic forms. The isolation and identification of four parasite species namely as zoonosis *Clinostomum complanatum*, *Eustrongylides excisus*, Plerocercoid *ligula intisetinalis* and anisakis larva constitute the new findings of the present research as it is the first time that their detection is reported in such fish species. Showing figures of parasites 5-17 related to figures 1-4.

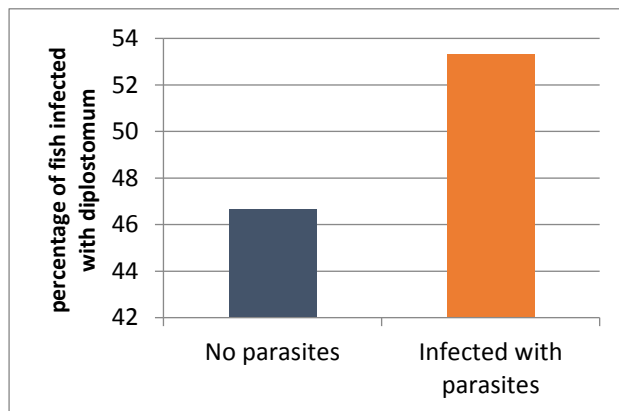


Figure 1. Percentage of *Chaleaiburnus chaleoides* infection with diplostomum parasite.

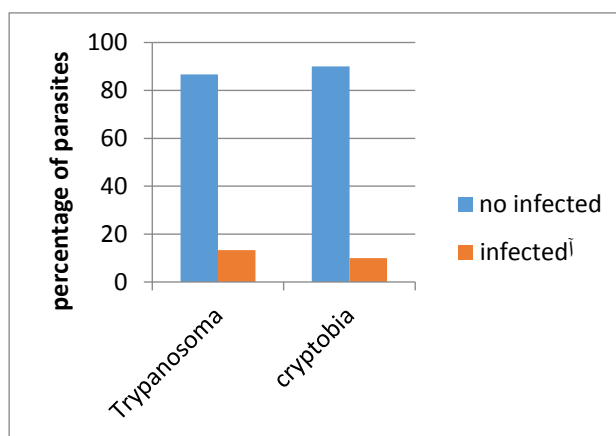


Figure 2. Percentage *Chaleaiburnus chaleoides* infection with blood parasite

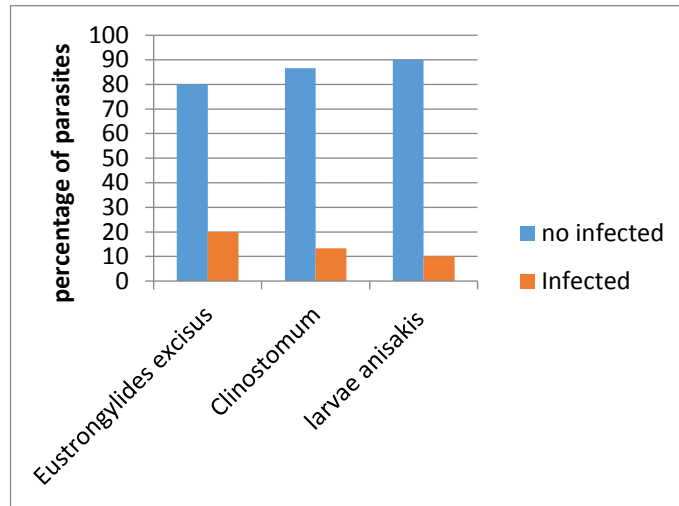


Figure 3. Percentage of infection of *Chaleaiburnus chaleoides* with internal parasites in the abdominal area.

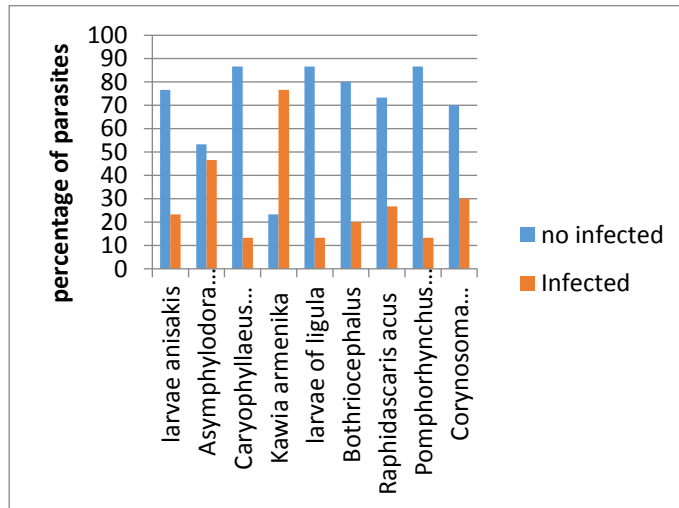


Figure 4. Percentage of *Chaleaiburnus chaleoides* infection with intestinal parasites.

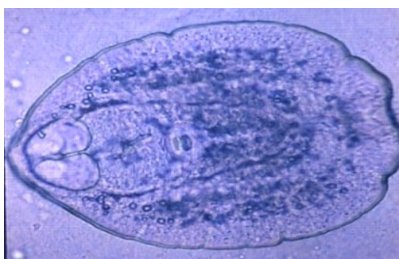

Figure 5. *Diplostomum spataceum* (Ob. lens, 40).

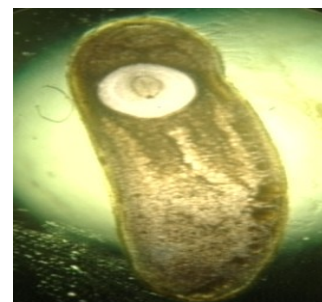

Figure 7. *Clinostomum complanatum* (Ob. lens, 40).

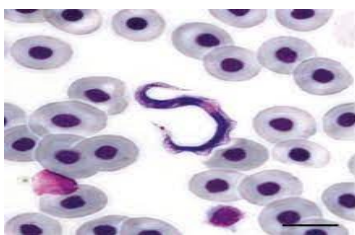


Figure 6. *Trypanosma percae* (Ob. lens, 100).



Figure 8. *Kawia armenika* (Ob. lens, 10).

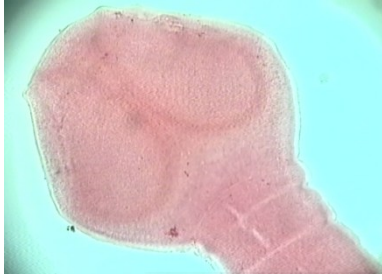

Figure 9. *Bothriocephalus gowkongensis* (Ob. lens, 10).

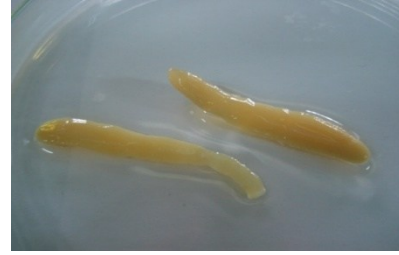

Figure 13. Plerocercoid larvae of *Ligola intestinalis* (Ob. lens, 10).

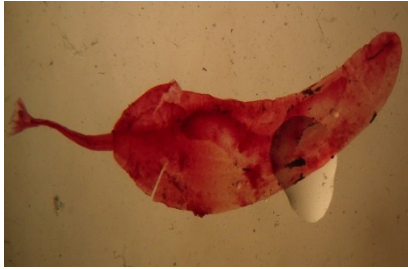


Figure 10. *Pomphorhynchus perforator* (Ob. lens, 10).

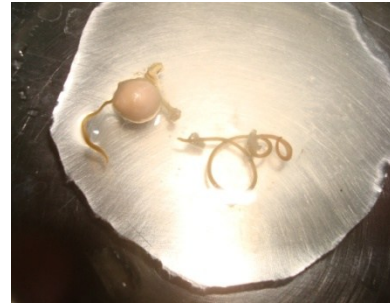

Figure 14. *Eustrongylides excisus* (Ob. lens, 10).

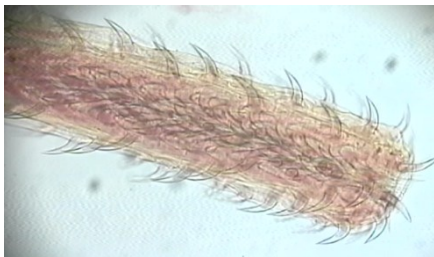

Figure 11. *Corynosoma capsicum* (Ob. lens, 40).

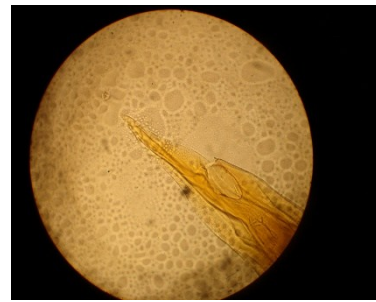


Figure 15. The posterior part of *Raphidascaris acus* (Ob. lens, 40).

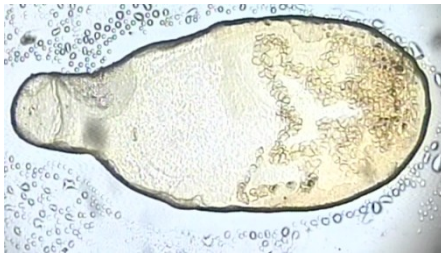


Figure 12. *Asymphylogora kubanicum* (Ob. lens, 40).

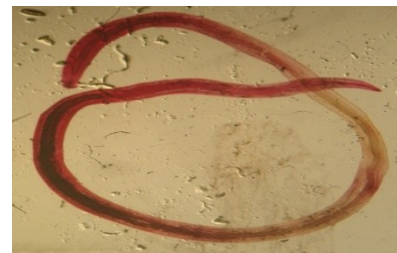

Figure 16. Larvae of *Anisakis* (Ob. lens, 10).



Figure 17. *Caryophyllaeus laticeps* (Ob. lens, 40).

Discussion

Sefidrood is currently an important habitat for different fish species. Various species of *Chalcalburnus chalcoides* annually migrate to southern Caspian Sea region and find their ways into the different estuaries and streams connected to “The Caspian Sea”. There has been scant parasitological research on different fish species of Sefidrood (Jalali, 1998; Woo, 2011). In addition, the discharge of extensive pollutant materials into the streams and the concomitant environmental degradation remarkably deteriorates the health status of aquatic species. The fish experience excessive stress under such environmental pollution, making them liable to a variety of ailments including parasitic diseases (Rahanandeh, 2021; Idowu, 2016; Noga, 2010). Since there have been insufficient parasitological studies, at least during the past three decades, dealing with parasitic infestation, an attempt was made here to, first, investigate *Chalcalburnus chalcoides* as, both an economically important species and a highly popular seafood for local consumption. Given the nutritional significance of *Chalcalburnus chalcoides* and the probability of people is being affected by zoonosis, it was decided to focus mainly on the internal parasites of fish. As shown in the presentation of results (Figures 1-4), 14 fish parasite species were isolated and identified, out of which zoonotic parasites accounted for four species. Consumers’ health affected by zoonotic contamination constitutes a highly significant sanitary issue and it is the first detected case, reported among *Chalcalburnus*

chalcoides. There have been many studies on parasitic identifications in various fish species. (Rahanandeh, *et al.*, 2010, Jalali, 1998) reported different internal parasites and Monogenic parasite of *Rutilus frisii kutum* in rivers flowing into the Southern Caspian Sea. Huseynov and Seid-Rzayev, 2016; Guseynov, 2010; Losev and Ovcharenko, 2003 identified *Cryptobia beverli* and trypanosome among 8 fishes in the rivers of Azerbaijan. It is evident that fish may be infected in different environmental situations to different parasites species due to the type of feeding behavior they have, their migration and birds of prey that act as the final host of the parasite, etc. for example, the leech present in water could play a crucial role as vectors of parasites in fish blood (Guseinov, 2013; Noga, 2010; Idowu, 2016). Two parasitic forms, *Trypanosoma percae* 13.3%, and *Cryptobia* sp. 10% were detected in *Chalcalburnus chalcoides* for the first time (Figure 2). These affected fish were caught in the sections of river with still water where the leech could possibly have contributed as disease vectors. *Diplostomum spathaceum* is a trematode with many cited detections among various fish species of Iran and in the rest of the world. In acute cases, this parasite could result in cataracts and/or blindness among fish (Jalali, 1998; Rahanandeh, 2021; Karvonen, 2004_{a,b}). In the present research, fish eyes infection were found to be 53.3% (Figure 1). Marcogliese, (2008) showed the effects of climate changes, rising water temperature and the abundant

intermediate and final hosts on the severity of infestation by Anisakis larvae. The report by Arizono, *et al.*, (2012) suggests that Anisakis simplex larvae resisted the intestinal acids and could easily find their way into the digestive tract, muscles and the ventricle chamber of fish. It is also the first time parasitic infestation of abdominal cavity (10%) and digestive tract (23.3%) by Anisakis larvae is reported (Figures 3, 4). *Metacercariae Clinostomum complanatum* was observed in various parts of fish body such as the muscles, mouth cavity, eyes, gills, subcutaneous tissue, gonads, guts, liver etc. (Vladi, *et al.*, 2002; Vianna *et al.*, 2003; Wang, *et al.*, 2017). Meanwhile, in this research, abundant number (13.3%) of *metacercariae Plorocercuoid cestod* in grubs yellow form was detected and isolated in the abdominal cavity of *Chalcalburnus chalcoides* with zoonosis as the second parasite detected in this species (Figure 3). Branciaro, *et al.*, (2016); Dezfuli *et al.*, 2015; and Agnetti, *et al.*, (2016) from Italy were the first to report the detection of *Eustrongylides excisus* in three fish species; *Atherina boyeri*, *Perca fluviatilis* and *Micropterus salmoides*. It is also the first time that *Eustrongylides excisus* is identified as a zoonotic parasite (20%) in the abdominal cavity of *Chalcalburnus chalcoides* (Figure 3). In a study by Rahanandeh, *et al.*, (2011) *Asymphyrodora kubanicum* was isolated from Caspian Sea *Rutilus frisii* kutum, while in this study the infestation percentage found was 46. In addition, Rahanandeh, *et al.*, (2011) detected parasitic infestation of juvenile *Rutilus frisii* kutum affected by *Bothriocephalus* in fishponds and among adult

Rutilus frisii kutum of Sefidrood and in this research the percentage of fish infestation by *Raphidascaris acus* was 20%. Schultz (*et al.*, 2008) reported the outbreak of disease among cyprinids (Chubb and Yeoman, 2008) with infestation percentage 20 caused by congenesis, *Khavia arminica*. The infestation percentages of *Chalcalburnus chalcoides* caused by cestode *Caryophyllaeus laticeps* is 13% and *Khavia armenica* is 76.6% respectively. Doosti and Yilmaz, (2020) reported a percentage of Ligula contamination in *Ladigesocypris irideus* fish in Turkish waters 42/85 and in this research it was found to be 13.3%. *Acantocephalus pomfericus proferator* was first detected among *Silurus glanis* by Seyed-Mortazaei, (2000), also Rahimi-Esboei, *et al.*, (2017) studied *Corisonoma caspicum* in *Gasterosteus aculeatus species* in the Caspian Sea. *Raphidascaris acus* nematode was reported in *Chalcaiburnus chalcoides* of Sefidrood River (Rahanandeh *et al.*, 2010). In this study, the infection rate in these fish is reported to be 26%. The study showed that infestation caused by *Pomfericus proferator* was 20% while *corinosoma Caspicum* resulted in 30% infestation percentage in *Chalcalburnus chalcoides*. The study showed the variation in the percentage and the prevalence of different parasites in this fish species. The new finding of the present research is the diagnosis of zoonotic parasites such as larvae of anisakis, *Eustrongylides excisus*, *Clinostomum complanatum*, *Plerocercoid ligula intisetinalis* in this fish species and that is the first reported case. Since the fish is an economically and

nutritionally important seafood amongst the local consumers, consumer is being infected by zoonotic parasites should be taken into consideration.

Acknowledgment

We are very grateful of the management and hardworking experts of Department Of Environment – Guilan Province who helped us in this research.

Conflicts of interest

None of the authors have any conflicts of interest to declare.

References

- Abbasi, A., valipour, A., Talebi haghghi, D., Sarpanah, A. and Nezami, Sh., 1999. Atlas of Iranian fishes Guilan Inland Waters, 1, 52. (In Persian)
- Agnetti, F., Sensidoni, L., Marrocchi, E.D.R., Lo Vaglio, G., Sgariglia, E., Valentini, A., Ghittino, C., Caffara, M., Gustinelli, A. and Fioravanti, M.L., 2016. Presence of Eustrongylides sp. (Nematoda: Dioctophymatidae) in fish species of the Trasimeno lake (Umbria): preliminary data [Conference poster]. In XVII Congresso Nazionale SI Di. LV, Pacengo di Lazise (VR), Italia, 28-30 settembre 2016 (pp. 253-254). Società Italiana di Diagnostica di Laboratorio Veterinaria (SIDiLV).
- Arabani, I., 2001. Gilan Book, Volume One, Iran Researchers Group Publications, E, 2, 69 (In Persian)
- Arizono, N., Yamada, M., Tegoshi, T. and Yoshikawa, M., 2012. Anisakis simplex sensu stricto and Anisakis pegreffii: biological characteristics and pathogenetic potential in human anisakiasis. *Foodborne pathogens and disease*, 9(6), 517-521. <https://doi.org/10.1089/fpd.2011.1076>
- Asgari, R., 2009. Systematic mathematics; Naghsh Mehr Publications, 87. (In Persian)
- Branciarri, R., Ranucci, D., Miraglia, D., Valiani, A., Veronesi, F., Urbani, E., Lo Vaglio, G., Pascucci, L. and Franceschini, R., 2016. Occurrence of parasites of the genus Eustrongylides spp. (Nematoda: Dioctophymatidae) in fish caught in Trasimeno lake, Italy. *Italian Journal of Food Safety*, 5, 6130. <https://doi.org/10.4081/ijfs.2016.6130>
- Bychowsky, B.E. 1949. Monogenetic trematodes of some fish of Iran, collected by E.N. pavlowsky (in Russian). *Zoologicheskogo Instituta AN SSSR*, 8, 870-878.
- Chubb, J.C. and Yeomans, W.E., 2008. *Khawia sinensis* Hsu, 1935 (Cestoda: Caryophyllidea), a tapeworm new to the British Isles: a threat to carp fisheries? *Fisheries Management and Ecology* 2(4), 263-277. <https://doi.org/10.1111/j.1365-2400.1995.tb00118.x>
- Dezfuli, B.S., Manera, M., Lorenzoni, M., Pironi, F., Shinn, A.P. and Giari, L., 2015. Histopathology and the inflammatory response of European perch, *Perca fluviatilis* muscle infected with Eustrongylides sp. (Nematoda).

Parasit. Vectors, 8, 227.
<https://doi.org/10.1186/s13071-015-0838-x>

Doosti, S. and Yilmaz, F. 2020. Occurrence of *Ligula* sp. plerocercoids in *Ladigesocypris irideus* (Ladiges, 1960) from South Western Turkey: new host and new locality records, 10(4), 2416 - 2423.
<https://doi.org/10.21597/jist.688296>

Guseinov, M.A., 2013. Parasitic protozoa blood of fish, amphibians and aquatic reptiles with Azerbaijan (fauna, systematics, ecology and biology) Author. diss. Cand. biol. Sciences. Baku, 311.

Guseynov, M.A., 2010. Fauna of parasitic protozoa blood carp and rudd problems some ponds of Azerbaijan. Intern. Scien. Conference Theoretical and practical of parasitology, Moscow, 101-105.

Gussev, A.V., Jalali, B. and Molnar, K., 1993a. Six new species of the genus *dactylogyrus* (Monogenea, Dactylogyridae) from Iranian freshwater fishes. zool. Inst. st. Petersburg, 29 - 35.

Huseynov, M.A. and Seid-Rzayev, M. M., 2016. Fish blood parasites from middle Kura basin of Azerbaijan JEZS 2016; 4(4), 726-729.

Idowu, T.A., Onyia, L.U. and Kefas. M., 2016. Fish diseases and health management. In: Contextual aquaculture and fisheries digest. Maiden Edition Paraclete Publisher, 155-171.

Jalali jafari, B., 1998. Parasites and parasitic diseases of Iranian freshwater fish Publications

of the Deputy of Reproduction and Breeding of Iran, 70-84. (In Persian)

Karimpour, m., Hosseinpour, N. and Haghghi D., 1992. Hemiculter lucisculus migrating to Anzali wetlan Guilan Fisheries Research Center, 23.

Karvonen, A., Seppa I. O. and Valtonen, E. T., 2004b. Parasite resistance and avoidance behaviour in preventing eye fluke infections in fish. *Parasitology*, 129, 159–164.
<https://doi.org/10.1017/S0031182004005505>

Karvonen, A., Seppa, I. O. and Valtonen, E. T., 2004a. Eye fluke-induced cataract formation in fish: quantitative analysis using an ophthalmological microscope. *Parasitology* 129, 473–478.
<https://doi.org/10.1017/S0031182004006006>

Kazancheev, E. N., 1981. Ryby Kaspiiskogo Morya [Fishes of the Caspian Sea]. Legkaya i Pischchevaya Promyshlennost, Moskva, 167, pp.

Losev, A.A. and Ovcharenko, N.A., 2003. Methodical bases of the study of blood parasites of fish. *Gidrobiol. Zh.* 39(6), 105-114.

Marcogliese, D.J., 2008. The impact of climate change on the parasites and infectious diseases of aquatic animals. *Revue scientifique et technique*, 27(2), 467-484.
<https://doi.org/10.20506/rst.27.2.1820>

Molnar, K. and Jalali, B., 1992. Further Monogeneans from Iranian freshwater fishes. *Acta ret. Hung.* 40, 55 – 61.

- Nikolskii, G.V., 1969. Theory of fish population dynamics as the biological background for national exploitation and managements of fishery resources. Oliver and Boyd, Edinburgh, Scotland, 323 p.
- Noga, E.J., 2010. Fish disease: Diagnosis and Treatment, Iowo state University Press, 10-25. <https://doi.org/10.1002/9781118786758>
- Patimar, R., Abdoli, A. and Kiabi, B.H., 2008. Biological characteristics of the introduced Sawbelly, *Hemiculter leucisculus* (Basilewski, 1855), in three wetlands of northern Iran: Alma-Gol, Adji-Gol and Ala-Gol. *Journal of Applied Ichthyology*, 24(5), 617-620. (In Persian) <https://doi.org/10.1111/j.1439-0426.2008.01080.x>
- Rahimi-Esboei, B., Najm, M., Shaker, M., Fakhar, M. and Mobedi, I., 2017. Prevalence of *Corynosoma caspicum* infection in *Gasterosteus aculeatus* fish in Caspian Sea, Northern Iran. *Veterinary World*, 10(9), 1139. <https://doi.org/10.14202/vetworld.2017.1139-1142>
- Scholz, T., Brabec, J., Hromadová, I.K., Oros, M., Bazsalovicsová, E., Ermolenko, A. and Hanzelová, V., 2011. Revision of *Khawia* spp. (Cestoda: Caryophyllidea), parasites of cyprinid fish, including a key to their identification and molecular, *Folia Parasitologica*. 58(3), 197–223. <https://doi.org/10.14411/fp.2011.020>
- Seyed-Mortazaei, S.R., Mobedi, I. and Farahnak, A., 2000. Helminths of freshwater fishes in Khuzestan Province. *Iranian Scientific Fisheries Journal*, 9 (1), 35–38.
- Vianna, R.T., Pereira, J., Brandao, D.A., 2003. Ontogenetic variation of metacercariae of *Clinostomum complanatum* (Rudolphi, 1814) (Digenea: Clinostomidae). *Comunicacoes do Museu de Ciencias e Tecnologia da PUCRS. Serie Zoologia*, Porto Alegre 16, 223–243.
- Vladi, T.V., Afzelius, B.A., and Bronnikov, G.E., 2002. Sperm quality as reflected through Morphology in salmon alternative life histories. *Biology of Reproduction*, 66(1), 98–105. <https://doi.org/10.1095/biolreprod66.1.98>
- Wang, M.L., Chen, H.Y. and Shih, H.H., 2017. Occurrence and distribution of yellow grub trematodes (*Clinostomum complanatum*) infection in Taiwan. *Parasitology research* 116(6), 1761–1771. <https://doi.org/10.1007/s00436-017-5457-3>
- Woo, P.T.K. 2011. Fish Diseases and Disorders, Volume 1, Protozoan and Metazoan Parasites, CAB international, U.K. 25-28.