First Report of *Ichthyophoniasis* in Angelfish, *Pterophyllum altum*, and Histopathology Study of Infected Fish

R Rahnama*, R Peyghan

Department of Aquatic Animal Health and Diseases, Faculty of Veterinary medicine, Shahid Chamran University of Ahvaz, Ahvaz, Iran

Received: August 2018 **Accepted:** October 2019

Abstract

Ichthyophonus is a unicellular fish parasite with a range of hosts and therefore a lot of economic losses. In this study, *Ichthyophonus* infection was reported in diseased angelfish, *Pterophyllum altum*. Samples were provided from three angelfish referred to veterinary hospital and examined by routine methods. The fish were lethargic with mild symptoms of chronic disease. According to a spherical shape and globular morphology of agent (characteristic spores surrounded by a thick fibrous membrane seen in squash preparations made from heart and spleen) and further histopathology and culture results, agent was described as *Ichthyophonus hoferi*. The result showed two main phases in the life of infecting parasites, 'active' and 'passive', the passive form is prone to convert to active. As another result, white-cream cysts were seen in infected organs. The most obvious macroscopic symptom of ichthyophonosis in angelfish was the spots on the skin and nodules in the heart. The cysts were filled with schizonts that were surrounded by fibroblasts, collagen fibers and many eosinophilic inflammatory cells. In the next step, tissue samples were also separated and incubated into Minimum Essential Medium (MEM) to see the germination of *Ichthyophonus hoferi*. This test was suggested for recognizing *Ichthyophonus* from Mycobacterial infections.

Keywords: *Ichthyophonus hoferi*, Histopathology, Angelfish, Ornamental fishes, Cysts

***Correspondence** R Rahnama, Department of Aquatic Animal Health and Diseases, Faculty of Veterinary medicine, Shahid Chamran University of Ahvaz, Ahvaz, Iran (e-mail: royarahnama60@yahoo.com).

Introduction

Ichthyophonus hoferi was recognized in salmonidae in Germany by von Hofer in 1893 for the first time. The disease agent was introduced as a fungus and called Ichthyophoniasis. *Ichthyophonus* infection can affect culture and aquarium fishes seriously, since it decreases the growth rates and eventually leads to death of fishes. In this situation it requires cost and time consuming actions for treatment (with usually uncertain successful results) of diseased fish (Mendoza, Taylor & Ajello 2002; Kocan 2013;

[Downloaded from ijaah.ir on 2026-11-23]

[DOR: 20.1001.1.2345315.2019.5.2.2.5]
[DOI: 10.29252/ijaah.5.2.1]

Hershberger, Gregg, Hart, Moffitt, Brenner, Stick & Lovy 2016). Recent phylogenetic researchers have classified this species as a Protozoa (class Ichthyosporea, more recently to Mesomycetozoea; order Ichthyophonida) (Gavryuseva 2007). Ichthyophonosis has detected from more than 100 fish species and resulted a worth mention mortalities and economic losses (Neish & Hughes 1980).

The pathological changes are typically chronic and very similar to tuberculosis. *Ichthyophonus hoferi* usually produces a systemic granulomatous infection in more vascularized organs such as heart, spleen, liver and kidney. Moreover, this parasite remain captured in the host after the invasion, generally demonstrates a 'dead end' in the host (Rahimian 1998; Kocan 2013).

Short acute phase and then long-term chronic phase infection has been seen by this parasite. Chronic phase is displayed by cell infiltration and progressive connective tissue encapsulation of spores. The disease may have coarse superficial and internal symptoms like roughened skin ('sandpaper effect') and white or cream-colored nodules (1 to 5 mm in size) in the skeletal muscle, liver or heart (Rahimian 1998; Mendoza et al. 2002.).

A few studies have reported *Ichthyophonus hoferi* in some ornamental fishes. Reichenbach-Klinke (1954, 1955) reported this pathogen in Sumatra barb (*Systomus tetrazona*) and black tetra (*Gymnocorymbus ternetzi*); Ozturk et al. (2010) in some organs of goldfish (*Carassius auratus*) and Sobecka (2012) detected *I. hoferi* in Discus fish (*Symphysodon.spp*) as the new host (all cited in: Zadeh, Peyghan & Manavi 2014).

Different studies have identified *Ichthyophonus* using different methods including macroscopic examination of tissues (Anonymous 1993), microscopic visualization of tissue squashes (Holst 1994; Rahimian & Thulin 1996), histological examination (Marty, Freiberg, Meyers, Wilcock, Farver & Hinton 1998; Kent, Reno, Watral, Dawe, Heidel & Jones 2001; Jones & Dawe 2002), in vitro culture of tissue explants (Hershberger, Stick, Bui, Carroll, Fall, Mork & Kocan 2002; Kocan, Hershberger, Sanders & Winton 2009; Halos, Hart, Hershberger & Kocan 2005), and polymerase chain reaction (PCR) using Ichthyophonus-specific primers (Whipps, Burton, Watral, Hilaire & Kent 2006). These literatures have pointed out that the result of each method could be different within the same population and even within the same individual. Thus various diagnostic methods are needed to accurately detect *Ichthyophonus*. In this study we applied macroscopic examination of tissues along with histological examination and culture of tissue in order to the identify *I. hoferi* in angelfish. In the current paper, the first case of Ichthyophoniasis in angelfish is reported based on microscopic structure and culture properties. In addition, morphology and pathology of *I. hoferi* in angelfish were described.

Materials and Methods

A few numbers of angelfish from pet shop was transferred to the veterinary hospital of Shahid Chamran University, Ahvaz, Iran. Three angelfish were observed to have some symptoms such as swimming disorders, loss of appetite, lethargy and abdominal swelling. Total length (T.L.) and body weight (B.W.) was

[Downloaded from ijaah.ir on 2026-11-23]

[DOR: 20.1001.1.2345315.2019.5.2.2.5]
[DOI: 10.29252/ijaah.5.2.1]

measured and health status of each fish was recorded. Angelfish had average length and body weight of 7.5 ± 0.5 cm and 5 ± 0.5 g, respectively. External gross examinations were performed by routine clinical methods. In the second step, wet and dry smear were prepared from spleen, heart and liver.

Tissue culture

Tissue samples were separated and put into the culture medium under the routine conditions. Samples from infected tissues were diluted with nine volumes of minimum essential medium (MEM, Sigma, St. Louis, Missouri, USA) containing Earle′ s salt, L-glutamine, 25 mM Heps, 10% fetal bovine serum (FBS), 100 ng ml^{-1} of streptomycin sulfate and 100 IU penicillin. Cultures were kept at 25°C and the tissue samples were checked regularly for two weeks. Eventually, the tissue dry smear was prepared and stained by Giemsa method (McVicar 1982; Halos, Hart, Hershberger & Kocan 2005; Kocan & Hershberger 2006).

Histopathological sampling and examination

For histopathologic study samples of heart, spleen and liver were fixed in formalin (10% phosphate-buffered formalin). Based on the standard techniques, samples were processed and sections stained either in hematoxylin-eosin or PAS (Drury & Wallington 1980; Beširović, Alić, Prašović & Drommer 2010; Sönmez, Bilen, Albayrak, Yılmaz, Biswas, Hisar & Yanık 2015).

Results

All diseased angelfish showed infection with *Ichthyophonus hoferi* in different organs. Two obvious signs in all fish were the presence of creamy white nodules (ranging from <60 μm up to 170 μm) on the internal organs (Fig 1 and 2) and also black spot on the body surface (Fig 3). The nodules were similar in terms of the appearance in most of the examined specimens. 'Giant nodules' were founded in spleen and heart, which can be caused by nodules joining. Granulomas were not observed in the liver and kidney.

Encapsulated and un-encapsulated schizont recognized in histopathological sections (Fig 4). There were about 4-6 fibrous layers or fibrotic capsule in encapsulated schizont that indicated the inactive phase, in the other hand some nodules were seen with thin fibrotic layer, which represented active phase. Hydropic degradation was also a prominent feature in infected spleens. In addition, black spots (melanin reaction) with different sizes (averagely 4.3 μm) observed in detected organs around schizonts (Fig 5). Development of new budding yeast of Plasmodium ending to club-shape cells confirms the Ichthyophonus (Fig 6). The results of squashed infected organs showed the presence of *Ichthyophonus hoferi* spores. Resting spores were seen in two forms; most of them were restricted by fibroblasts and maturing collagenous and the others were restricted by activated macrophages. Histopathologic examination of the lesion of heart showed severe granulomatous inflammation which was associated with developing spores.

[Downloaded from ijaah.ir on 2026-11-23]

[DOR: 20.1001.1.2345315.2019.5.2.2.5]
[DOI: 10.29252/ijaah.5.2.1]



Figure 1. Gross sign of ichthyophonosis on the heart of heavily infected angelfish. The myocardium and balbus arteriosus are filled with white/tan nodules.



Figure 2. Numerous white/tan nodules are noted in the parenchyma and protruding from the serosal surface of the infected pale spleen of angelfish.



Figure 3. Skin lesion in caudal peduncle of infected angelfish.

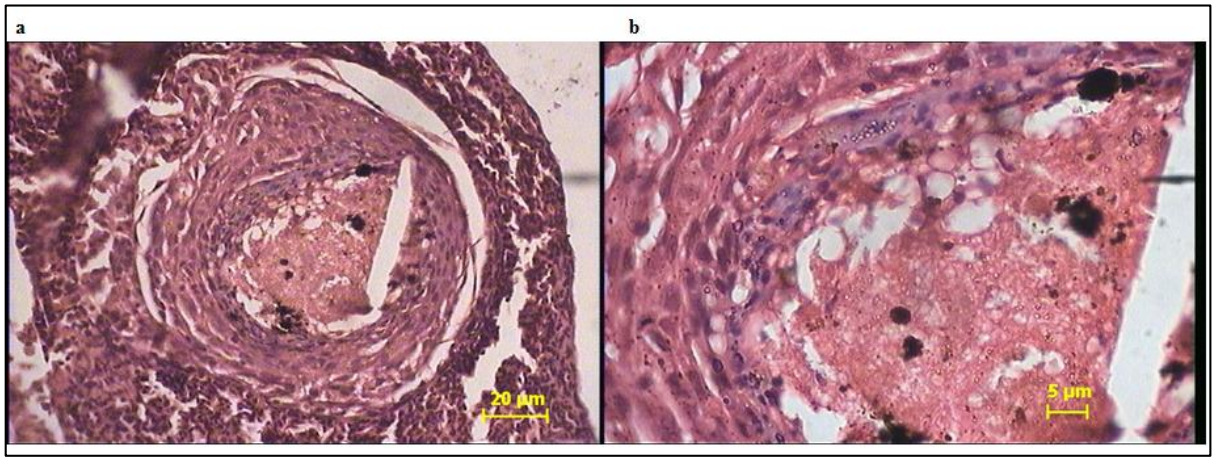

Figure 4. a: A granulomatous mass with multi-nucleate spore of *Ichthyophonus* in the spleen of angelfish (×40, H&E). b: resting spores of *I. hoferi* in the spleen with signs of degeneration (×100, PAS).

[Downloaded from ijaah.ir on 2026-11-23]

[DOR: 20.1001.1.2345315.2019.5.2.2.5]
[DOI: 10.29252/ijaah.5.2.1]

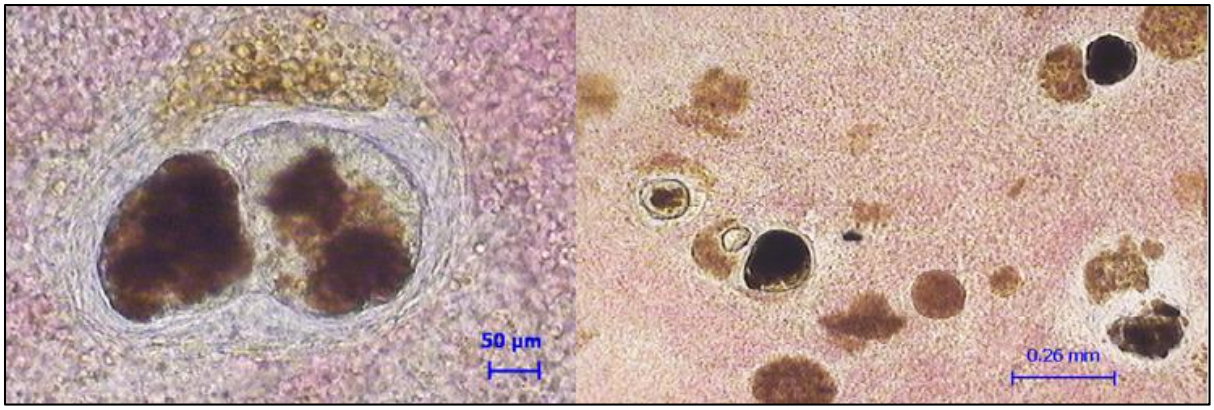

Figure 5. Squash preparation from spleen nodules showing the spores of *Ichthyophonus hoferi* (Passive spores).



Figure 6. Single non-septate hyphae produced in *Ichthyophonus* tissue culture.

Discussion

The results of current study indicated that all sampled fish were suffered from Ichthyophoniasis. This disease could infect the marine fish more than fresh water fish (Spanggaard, Gram, Okamoto & Huss 1994; LaPatra & Kocan 2016). Depending on the host, the diseases symptoms may also be considerably differ among fish species (Gavryuseva 2007). Bloodstream or lymphatic system transmits *Ichthyophonus* to all parts of the host body especially blood-rich organs such as liver, heart and spleen. Histological and histochemical investigations revealed thick-walled multinucleate resting spores of *Ichthyophonus hoferi* in the liver, kidney, heart, skeletal muscles, pancreas, fatty and connective tissues of fish. The immune system of fish deal with the parasite may lead to two types of acute and chronic reactions (Zadeh et al. 2014). Sindermann and Scattergood (1954) and Hershberger et al. (2002) have reported acute case in herring appeared some signs such as replacement of tissues by the parasites mass, roughened skin and nodules.

One especial characteristic of this parasite is appearing severe responses around the schizonts. The resting schizonts could be observe in tissues and appears roughly circular with thick fibrous wall. The pathological study showed two forms of schizonts including developed and undeveloped which also defined by few authors (Rahimian 1998); Zadeh et al.

[Downloaded from ijaah.ir on 2026-11-23]
[DOR: 20.1001.1.2345315.2019.5.2.2.5]
[DOI: 10.29252/ijaah.5.2.1]

2014). Additionally, it is indicated that the active and passive phases of diseases are related to the parasite and the acute and chronic status are related to the host. In the current study, considering the nodulation and body reaction, both phases, active and passive, were detected.

In the present study, any examined fish show external signs on the surface of body and muscles; however, this parasite engaged to inner organs of all examined fish. Also infected fishes may indicate some non-specific signs include behavioral changes and changes associated with organs such as swimming abnormalities and loss of pigment control.

The results of our histopathology investigation showed the reaction of the host as two different responses. The infected spleen of angelfish had encapsulated schizont with thick layers of fibrous reaction. Similar histopathological changes in organs during *Ichthyophonus* disease were reported for young Chinook salmon *Oncorhynchus tschawytscha* (Jones and Dawe, 2002), brook trout *Salmo trutta* (Schmidt-Posthaus, and Wahli 2002), rainbow trout *Oncorhynchus (Parasalmo) mykiss* (Miyazaki and Kubota 1977), and Atlantic herring *Clupea harengus* (Donetskov 2004). Pathological changes were found in the liver, kidney, and spleen for the rockfish, *Sebastes flavidus* and *S. alutus* (Kent et al. 2001). Previous histopathological studies have noted that *Ichthyophonus* in fish tissue often is associated with the occurrence of melanomacrophages, giant cells, melanin and a thick layer of fibrocysts (Rahimian 1998; McVicar 1999; Huntsberger, Hamlin, Smolowitz & Smolowitz 2017).

Based on the results, the first response of the host to *Ichthyophonus* infection was an increase in the activity of leucocytes (specifically eosinophilic granulocytes), which surround the parasite; though, in this case, parts of leucocytes dies (Al-Jubury, LaPatra, Christensen, Zuo, Tafalla & Buchmann 2016). This process is accompanied by the appearance of fibrocytes, which surround (with one or several layers of elongate cells) the resting spore of *I. hoferi*, leucocytes, and necrotic cells, thus resulting in the formation of a characteristic granuloma. In other cases, *Ichthyophonus* spores can be surrounded by elongate radial epithelioid cells enclosed by a connective-tissue capsule (Gavryuseva 2007). Previous studies have demonstrated that pathogenicity of *Ichthyophonus sp*. is highly variable depending on hosts and environmental conditions (Kocan et al. 2009; Huntsberger et al. 2017). In one study, *Ichthyophonus* was microscopically identified penetrating the stomach epithelium of the goby (*Glossogobius giuris*) three days after infection. The parasite caused massive secondary infection in similarly treated rainbow trout (*Oncorhynchus mykiss*) after 8 days, resulting in visible nodules (McVicar 1982).

Incubation of schizonts in MEM is one of the most important ways for identification this parasite. In this study, using this method, the development of new budding yeast of Plasmodium ending to club-shaped cells supposed for *Ichthyophonus* confirmation. Such observations have also been reported by other researchers (Rahimian, 1998; LaPatra & Kocan 2016).

[Downloaded from ijaah.ir on 2026-11-23]

[DOR: 20.1001.1.2345315.2019.5.2.2.5]
[DOI: 10.29252/ijaah.5.2.1]

Chemoprophylactic and chemotherapeutic means that *Ichthyophonus sp*. infection control are still not known. The use of sanitary measures, including pasteurization of potentially infected feeds, can prevent the disease outbreak in hatchery-reared fish. Because dead fish are a serious source of infection, they must be eliminated in compliance with the practice adopted in culture fisheries (Gavryuseva 2007; LaPatra & Kocan 2016). In recent years, the aquarium industry in Iran has been developed as well as some other countries. But so far, there is no report from the isolation of this fungus in the angelfish in Iran. Moreover, there is a lack of information on the identification and characterization of fungal diseases of ornamental fishes. Such information is also important for same diseases in cultured fishes and fisheries management. The risk of fungal infectious diseases in ornamental fishes increase due to the poor aquarium management science. Also the basic health management practices could be simply unnoticed due to lack of expert personals. In order to decrease the chance of spreading fungal infection in the native fish species, control on the import of diseased fish into the country is urgently required. This is the first report of *Ichthyophonus hoferi*, in angelfish, (*Pterophyllum altum*) in Iran.

Acknowledgment

This research was part of an investigation on the infectious diseases study of aquarium fishes of Ahvaz. Financial support of research deputy of Shahid Chamran University, Ahvaz, Iran is appreciated.

Conflict of interests

The authors declare that there is no conflict of interest

References

Agius C. (1979) The role of melano-macrophage centres in iron storage in normal and diseased fish. *Journal of Fish Diseases 2*(4), 337-343. https://doi.org/10.1111/j.1365-2761.1979.tb00175.x.

Agius C. & Roberts R. J. (2003) Melano-macrophage centers and their role in fish pathology. *Journal of fish diseases 26*(9), 499-509.https://doi.org/10.1046/j.13652761.2003.00485.x.

Al-Jubury A., LaPatra S., Christensen N. D., Zuo S., Tafalla C. & Buchmann K. (2016) Exclusion of IgD-, IgT-and IgM-positive immune cells in Ichthyophonus-induced granulomas in rainbow trout *Oncorhynchus mykiss* (Walbaum). *Journal of fish diseases 39*(11), 1399-1402. https://doi.org/10.1111/jfd.12475.

Anonymous (1993) Report of the 2nd special meeting on Ichthyophonus in herring. ICES CM 1993/F: 9, International Conference on Exploration of the Sea 1993, Copenhagen, Denmark.

Beširović H., Alić A., Prašović S. & Drommer W. (2010) Histopathological effects of chronic exposure to cadmium and zinc on kidneys and gills of brown trout (*Salmo trutta* m. fario). *Turkish Journal of*

[Downloaded from ijaah.ir on 2026-11-23]

[DOR: 20.1001.1.2345315.2019.5.2.2.5]

[DOI: 10.29252/ijaah.5.2.1]

Fisheries and Aquatic Sciences 10(2), 255-262. https://doi.10.4194/trjfas.2010.0000.

Donetskov V.V. (2004) Effect of *Ichthyophonus* Epizootic on Population of Atlantic Scandinavian Norwegian Spring Spawning) Herring (*Clupea harengus harengus* L.), *Abstract of Cand. Sci. (Biol.) Dissertation*, MGTA, Moscow. Francisco, CA, pp. 641.

Gavryuseva T. V. (2007) First report of Ichthyophonus hoferi infection in young coho salmon *Oncorhynchus kisutch* (Walbaum) at a fish hatchery in Kamchatka. *Russian Journal of Marine Biology 33*(1), 43-48. https://doi.org/10.1134/S106307400701004X.

Halos D., Hart S.A., Hershberger P. & Kocan R. (2005) Ichthyophonus in Puget Sound rockfish from the San Juan Islands Archipelago and Puget Sound, Washington, USA. *Journal of Aquatic Animal Health 17*(3), 222-227. https://doi.org/10.1577/H04-041.1.

Hershberger P.K., Gregg J.L., Hart L.M., Moffitt S., Brenner R., Stick K., Coonradt E., Otis E.O., Vollenweider J.J., Garver K.A. & Lovy J. (2016) The parasite Ichthyophonus sp. in Pacific herring from the coastal NE Pacific. *Journal of fish diseases 39*(4), 395-410. https://doi.org/10.1111/jfd.12370.

Hershberger P.K., Stick K., Bui B., Carroll C., Fall B., Mork C. & Kocan R. (2002) The incidence of *Ichthyophonus hoferi* in Puget Sound fishes and its increase with age of Pacific herring. *Journal of Aquatic Animal Health 14*(1), 50-56. https://doi.org/10.1577/1548-8667 (2002)014%3C0050.

Holst J. C. (1994) The precision of two macroscopic screening procedures relative to a microscopic procedure for screening of the fungus Ichthyophonus hoferi in herring (*Clupea harengus* L.). *Fisheries Research 19*(1-2), 187-190.https://doi.org/10.1016/0165-7836 (94)90023- X.

Huntsberger C. J., Hamlin J. R., Smolowitz R. J. & Smolowitz R. M. (2017) Prevalence and description of Ichthyophonus sp. in yellowtail flounder (*Limanda ferruginea*) from a seasonal survey on Georges Bank. *Fisheries Research 194*, 60-67. https://doi.org/10.1016/j.fishres.2017.05.012.

Jones S.R.M. & Dawe S.C. (2002) *Ichthyophonus hoferi* Plehn & Mulsow in British Columbia stocks of Pacific herring, *Clupea pallasi* Valenciennes, and its infectivity to chinook salmon, *Oncorhynchus tshawytscha* (Walbaum). *Journal of Fish Diseases 25*(7), 415-421. https://doi.org/10.1046/j.13652761.2002.00390.x.

Kent M.L., Watral V., Dawe S.C., Reno P., Heidel J.R. & Jones S.R.M. (2001) Ichthyophonus and Mycobacterium-like bacterial infections in commercially-important rockfish, Sebastes spp., in the eastern North Pacific Ocean. *Journal of Fish Diseases 24*(7), 427-431. https://doi.org/10.1046/j.1365-2761.2001.00313.x.

[Downloaded from ijaah.ir on 2026-11-23]

[DOR: 20.1001.1.2345315.2019.5.2.2.5]

[DOI: 10.29252/ijaah.5.2.1]

Kocan R.M. (2013) Proposed changes to the nomenclature of Ichthyophonus sp. life stages and structures. *The Journal of parasitology 99*(5), 906-909. https://doi.org/10.1645/13-177.1.

Kocan R. & Hershberger P. (2006) Differences in Ichthyophonus prevalence and infection severity between upper Yukon River and Tanana River Chinook salmon, *Oncorhynchus tshawytscha* (Walbaum), stocks. *Journal of Fish Diseases 29*(8), 497-503. https://doi.org/10.1111/j.1365-2761.2006.00743.x.

Kocan R., Hershberger P., Sanders G. & Winton J. (2009) Effects of temperature on disease progression and swimming stamina in Ichthyophonus-infected rainbow trout, *Oncorhynchus mykiss* (Walbaum). *Journal of Fish Diseases 32*(10), 835-843. https://doi.org/10.1111/j.1365 2761.2009.01059.x.

LaPatra S. E. & Kocan R. M. (2016) Infected Donor Biomass and Active Feeding Increase Waterborne Transmission of *Ichthyophonus* sp. to Rainbow Trout Sentinels. *Journal of aquatic animal health 28*(2), 107-113. https://doi.org/10.1080/08997659.2016.1159623.

Mansor N.T., Falah A.B., Al- Jawda J.M. & Asmar K.R. (2012) Histopathological study of some Tigris River fish which infected by parasites. *The veterinary Journal of Iraq* 36, 33-42.

Marty G. D., Freiberg E. F., Meyers T. R., Wilcock J., Farver T. B. & Hinton D. E. (1998) Viral hemorrhagic septicemia virus, *Ichthyophonus hoferi*, and other causes of morbidity in Pacific herring *Clupea pallasi* spawning in Prince William Sound, Alaska, USA. *Diseases of Aquatic Organisms 32*(1), 15-40. https://doi:10.3354/dao032015.

McVicar A.H. (1982) Ichthyophonus infections in fish. In: Microbial Diseases of Fish (Roberts, R.J., Ed.) pp 243-269. Academic Press, London.

Mendoza L., Taylor J. W. & Ajello L. (2002) The class Mesomycetozoea: a heterogeneous group of microorganisms at the animal-fungal boundary. *Annual Reviews in Microbiology 56*(1), 315-344. https://doi.org/10.1146/annurev.micro.56.012302.160950.

Miyazaki T. & Kubota S. (1977) Studies on the ichthyophonus disease of fishes, 3: Life cycle of ichthyophonus affected rainbow trout. *Bulletin of the Faculty of Fisheries Mie University*.

Neish G. A. & Hughes G. C. (1980) Fungal disease of fishes. TFH Publ. *Inc., Neptune.*

Rahimian H. (1998) Pathology and morphology of *Ichthyophonus hoferi* in naturally infected fishes off the Swedish west coast. *Diseases of Aquatic Organisms 34*(2), 109-123. https://doi:10.3354/dao034109.

Rahimian H. & Thulin J. (1996) Epizootiology of *Ichthyophonus hoferi* in herring populations off the Swedish west coast. *Diseases of Aquatic Organisms 27*(3), 187-195. https://doi:10.3354/dao027187.

[Downloaded from ijaah.ir on 2026-11-23]

[DOR: 20.1001.1.2345315.2019.5.2.2.5]

[DOI: 10.29252/ijaah.5.2.1]

Rand T.G. (1994) An unusual form of *Ichthyophonus hoferi* (Ichthyophonales: Ichthyophonaceae) from yellowtail flounder *Limanda ferruginea* from the Nova Scotia shelf. *Diseases of aquatic organisms 18*(1), 21-28. http://dx.doi.org/10.3354/dao018021.

Reichenbach-Klinke, H. H. (1954). Weitere Mitteilung über den Kiemenparasiten. *Zeitschrift für Parasitenkunde 16*(5-6), 373-387.

Schmidt-Posthaus H. & Wahli T. (2002) First report of *Ichthyophonus hoferi* infection in wild brown trout (*Salmo trutta*) in Switzerland. *Bull. Eur. Assoc. Fish Pathol 22*(3), 225-228.

Sönmez A. Y., Bilen S., Albayrak M., Yılmaz S., Biswas G., Hisar O. & Yanık T. (2015) Effects of dietary supplementation of herbal oils containing 1, 8-cineole, carvacrol or pulegone on growth performance, survival, fatty acid composition, and liver and kidney histology of rainbow trout (*Oncorhynchus mykiss*) fingerlings. https://doi. 10.4194/1303-2712-v15_4_04.

Spanggaard B., Gram L., Okamoto N. & Huss H. H. (1994) The growth of the fish-pathogenic fungus, *Ichthyophonus hoferi*, measured by conductimetry and microscopy. *Journal of Fish Diseases 17*(2), 145-153. https://doi.org/10.1111/j.13652761.1994.tb 00207.x.

Whipps C.M., Burton T., Watral V.G., St Hilaire S. & Kent M. L. (2006) Assessing the accuracy of a polymerase chain reaction test for *Ichthyophonus hoferi* in Yukon River Chinook salmon *Oncorhynchus tshawytscha*. *Diseases of Aquatic Organisms 68*(2), 141-147. https://doi:10.3354/dao068141.

Zadeh M. J., Peyghan R. & Manavi S. E. (2014) The Detection of *Ichthyophonus hoferi* in naturally infected fresh water Ornamental fishes. *J. Aquac. Res. Development 5*, 289. http://dx.doi.org/10.4172/2155-9546.1000289.

[Downloaded from ijaah.ir on 2026-11-23]

[DOR: 20.1001.1.2345315.2019.5.2.2.5]

[DOI: 10.29252/ijaah.5.2.1]

اولین گزارش از ایکتیوفونیازیس در ماهی آنجل، *Pterophyllum altum*، و مطالعه بافت شناسی ماهیان آلوده

رویا رهنما*، رحیم پیغان

گروه بهداشت و بیماری‌های آبزیان، دانشکده دامپزشکی، دانشگاه شهید چمران اهواز، اهواز، ایران

چکیده

ایکتیوفونوس یک انگل تک سلولی ماهی است که دارای طیف وسیعی از میزبان بوده و خسارات اقتصادی زیادی را می‌تواند به همراه داشته باشد. در این مطالعه، عفونت ایکتیوفونیازیس در ماهی آنجل، *Pterophyllum altum* گزارش شده است. نمونه ها از سه ماهی آنجل ارجاع شده به بیمارستان دامپزشکی تهیه و با روش‌های معمول مورد بررسی قرار گرفتند. ماهی‌های ارجاع داده شده بی‌حال بودند و علائم خفیف بیماری مزمن را نشان دادند. با توجه به شکل کروی و مورفولوژی گلبولار عامل بیماری (اسپورهای مشخصه احاطه شده توسط غشای فیبری ضخیم که در لام مرطوب تهیه شده از قلب و طحال مشاهده شد) و همچنین نتایج بررسی‌های بافت شناسی، عامل بیماری *Ichthyophonus hoferi* تشخیص داده شد. نتایج حاصل نشان دهنده دو مرحله اصلی در زندگی انگل‌های آلوده است – مرحله "فعال" و "غیرفعال"- و مرحله غیرفعال مستعد تبدیل به فازفعال است. قسمت دیگر نتایج هم وجود کیست‌های کرم سفید رنگ را در اندام‌های آلوده نشان داد. بارزترین علائم ماکروسکوپی ایکتیوفونوس در ماهی آنجل، وجود لکه های تیره بر روی پوست و همچنین گره‌های سیاه رنگ در قلب بود. کیست‌ها حاوی شیزونت‌های فراوانی بود که توسط فیبروبلاست‌ها، الیاف کلاژن و بسیاری از سلول‌های التهابی ائوزینوفیلی احاطه شده بودند. در مرحله بعد، برای دیدن جوانه زنی *Ichthyophonus hoferi* نمونه‌های بافتی جدا گردید و در Minimum Essential Medium (MEM) انکوبه شدند. این آزمایش برای شناسایی ایکتیوفونوس از عفونت‌های مایکوباکتریایی ضروری است.

کلمات کلیدی: *ایکتیوفونوس هوفری*، بافت شناسی، ماهی آنجل، ماهی‌های زینتی، کیست‌ها

***نویسنده مسئول:** royarahnama60@yahoo.com

[Downloaded from ijaah.ir on 2026-11-23]

[DOR: 20.1001.1.2345315.2019.5.2.2.5]

[DOI: 10.29252/ijaah.5.2.1]