

Histological Description of intestine and Gut Associated Lymphoid Tissue in *Esox Lucius* from Anzali wetland

N Salamat

Department of Marine Biology, Faculty of Marine Science, Khorramshahr University of Marine Science and Technology, Khorramshahr, Iran

Received: December 2017

Accept: March 2018

Abstract

Study of gut tissue structure in fish is important as the fish culture increases and then, more information is required regarding to feeding and nourishment. Then, the present study aimed to describe the histological and histochemical characteristics of GALT in the pike, *Esox lucius*, from the Anzali wetland. In this regards, 20 *E. lucius* were collected from the Anzali wetland. Tissue samples from different parts of gut were fixed in Bouin's solution. Tissue slides were prepared using tissue preparation techniques and stained with hematoxylin and eosin (H&E), Periodic acid-Schiff (PAS), Alcian blue and AB-PAS. In *E. lucius* the internal surface of gut was folded and coated by simple columnar cells and goblet cells. Goblet cells positively reacted to PAS, AB and AB-PAS, due to mix acidic and neutral glycoproteins containing.

Correspondence N Salamat, Department of Marine Biology, Faculty of Marine Science, Khorramshahr University of Marine Science and Technology, Khorramshahr, Iran, (e-mail: salamatnegin@yahoo.com)

Eosinophilic granular cells were detected in lamina propria. GALT represented throughout the gut mucosa in the epithelium and lamina propria. Lymphocytes increased in number toward the posterior part of intestine ($p < 0.05$).

Keywords: Gut, GALT, *Esox lucius*, Histology, Anzali wetland

Introduction

In mammals, the presence of two sites of gut mucosal immune system has been well documented: 1. the induction sites (gut-associated lymphoid tissue (GALT)) and, 2. the effector sites: lamina propria lymphocyte (LPL) and the intraepithelial lymphocyte (IEL) compartment (Brandtzaeg & Pabst (2004); Brandtzaeg et al. (2008)). GALT, especially the Peyer's patches (PP), play an important role in immune defense against antigens injected to the digestive tube. Memory cells (M-cells) presented in the epithelium over the induction sites, can strongly move exogenous antigens to the underlying lymphoid tissue that cause IgA

secretion at the effector sites (Brandtzaeg & Pabst (2004); Brandtzaeg et al. (2008)). Peyer's patches, M cells, IgA and also lymph nodes are not reported in teleost fish (Brandtzaeg et al. 2008). Therefore, the presence of a common mucosal immune system is almost excluded, but local mucosal defense system is reported repetitively (Cerutti 2008). Although, there is only a little information about the GALT in fish, but fish have more diffusely organized immune system in their gut, which is morphologically and functionally different from that in mammals. Gut immune system of fish contain all immune cells necessary for a local immune response including many lymphoid cells, macrophages, eosinophilic and neutrophilic granulocytes (Rombout et al. 2010).

Lymphocytes and T-cells in the gut intraepithelial and lamina propria capture the antigens and make the appropriate immune responses such as production of cytokines and specific antibodies (Kucharzik et al. 2000) and antigen detection preservation in memory cells (Cheroutre & Madakamutil 2005). Although, fish lack Peyer's patches and antigen-transporting M cells, the enterocytes in the hindgut have an antigen transporting capability and also many macrophages and lymphoid cells are distributed among the epithelial cells and lamina propria (Temkin & McMillan (1986); Rombout et al. (1993a)).

The pike (*Esox Lucius*), collected from the Anzali wetland, is one of the most important marine fish species with wild distribution. Due to lack of knowledge about the structure of gut associated lymphoid tissue in *E. Lucius*, this

research was carried out to describe the general histological structure of intestine and distribution of gut associated lymphoid tissue in this fish.

Materials and Methods

Totally, 20 male and female *E. lucius* (253.2 ± 12.91 g in weight and 32.65 ± 0.45 cm in length) were collected from different parts in the Anzali wetland during April 2013. The fish were dissected after euthanizing by 2- phenoxy ethanol. Tissue samples were collected from different parts (anterior, middle and posterior) of gut and fixed in Bouin's solution for 48 h. The tissue specimens were then dehydrated in ascending concentrations of ethanol series, embedded in paraffin, and sectioned at 5 mm to 6 mm. The tissue sections were stained with hematoxylin and eosin (H&E), Periodic Acid Schiff (PAS), Alcian Blue (AB) (pH=2.5) and PAS-AB (Cinar & Senol 2006) and then microscopic evaluation was performed for histological and histometrical study using light microscope with Dino lit lens (with Dino capture software).

Histological sections of intestine were submitted to counting of intraepithelial lymphoid cells. Six microscopic fields per section and five sections per fish were used for histometrical evaluation. Parametric (One Way ANOVA, Tukey Post Hac) and Non-parametric (Kruskal-Wallis Hand Mann-Whitney U) test were performed to determine the significant differences between the histometrical parameter in different parts of intestine. SPSS16.00 was used for all tests in 0.05 confidence level.

Results

Macroscopically, a short length and thickened wall intestine was observed in *E. lucius*. According to the results the tissue structure of intestinal wall in *E. lucius*, followed the same pattern as other vertebrates: tunica mucosa, tunica muscularis and tunica serosa (Fig. 1). In this fish mucosa comprised of two sub-layers: 1. the lining epithelium consisted of simple tall columnar cells with a basal nucleus and apical brush border and interspersed mucus secreting goblet cells and intraepithelial lymphocytes (IELs) (Fig. 2), 2. lamina propria / submucosa of irregular connective tissue with heavy lymphocytic infiltration (Fig. 2). The muscularis mucosa did not observed between lamina propria and submucosa, and then separation of these two layers was difficult. The gut mucosa had abundant folds, the length of which didn't significantly differ among different parts of intestine.

Tunica muscularis consisted of two layers of smooth muscle: inner circular and outer longitudinal (Fig. 1). Tunica serosa (loose connective tissue coated by simple squamous epithelial cell) surrounded the outer surface of gut (Fig. 1). Many nerve plexuses (Auerbach's plexuses) located between the two muscle.

Epithelial mucous cells, distinguished by a swollen supranuclear region, secreted neutral mucus which was stained purple with the PAS technique. These cells were also stained blue with AB and dark blue with AB-PAS (AB pH = 2.5) due to strong presence of neutral and acid mucus. The goblet cells significantly ($p < 0.05$) increased in number toward the posterior part of gut (Fig. 3). Massive capillary network was detected in lamina propria immediately beneath epithelial layer.

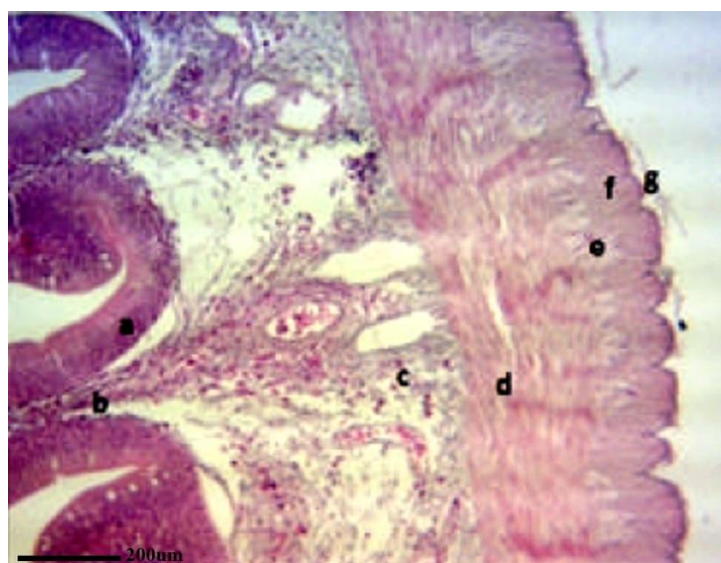


Figure 1. Intestinal wall in *E. lucius*: a. epithelium, b. lamina propria, c. submucosa, d. circular muscle layer, e. Auerbach's plexuses, f. longitudinal muscle layer, g. serosa, (H&E; $\times 290$).

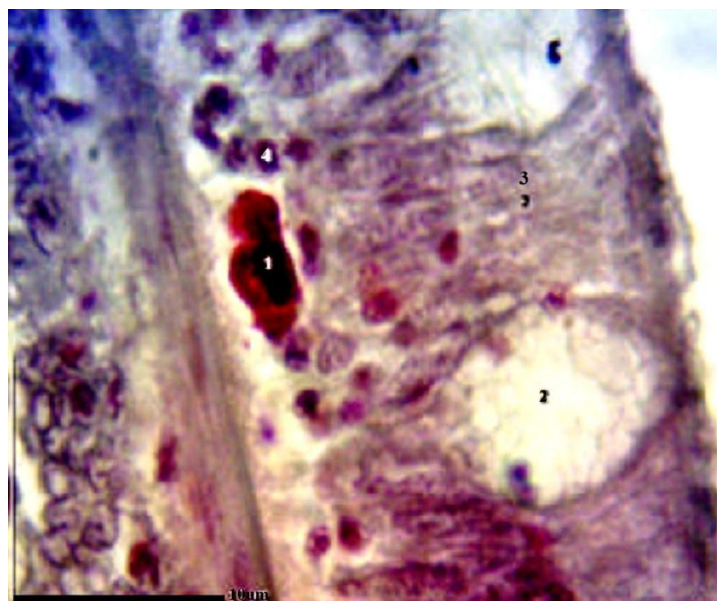


Figure 2. Intestinal epithelium: 1. Eosinophilic granular cell, 2. goblet cell, 3. columnar epithelial cells, 4. Intraepithelial lymphocyte (IEL) (H&E;×2900).

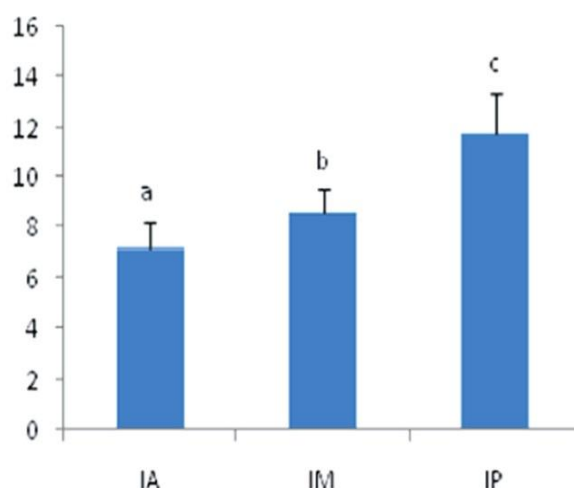


Figure 3. Goblet cells increase toward posterior intestine ($p<0.05$), AI: anterior intestine, MI: middle intestine, PI: posterior intestine.

Gut Associated Lymphoid Tissue (GALT)

GALT was demonstrated as individual cells or some small accumulations in the epithelium and lamina propria throughout the gut. IELs were found in apical and basolateral areas of intestinal cells, but the basolateral lymphocytes were more than those identified in apical area. The mean number of intraepithelial lymphocytes

in the intestine mucosa represented in Figure (4). Significant ($p<0.05$) difference was observed in the number of IELs through the length of the gut mucosa. IELs found in apical region of enterocytes significantly ($p<0.05$) increased in number to the posterior part of the intestine (Fig. 5).

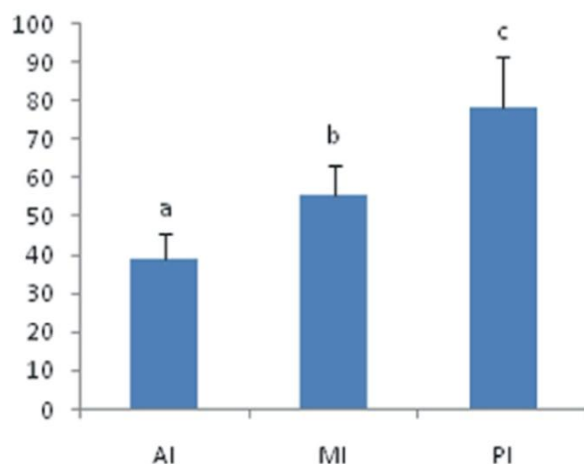


Figure 4. The amounts of IELs along the length of the intestine ($p < 0.05$), AI: anterior intestine, MI: middle intestine, PI: posterior intestine.

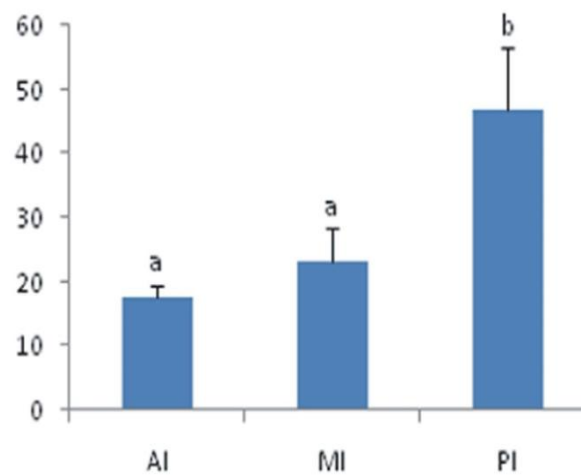


Figure 5. Increase of apical IELs toward the posterior intestine AI: anterior intestine, MI: middle intestine, PI: posterior intestine.

There were numerous lymphocyte, macrophage, plasma cell and eosinophilic granular cells / mast cell in lamina propria and submucosa. The cells with heterochromatin nucleus surrounded by a thin edge of basophilic cytoplasm were identified as lymphocytes (Fig. 6), the number of

which significantly increased in the lamina propria to the posterior part of intestine, where a few lymphocyte accumulations were observed. Plasma cells were more detected in lamina propria. Eosinophilic granular cells were found in stratum granulosum layer.

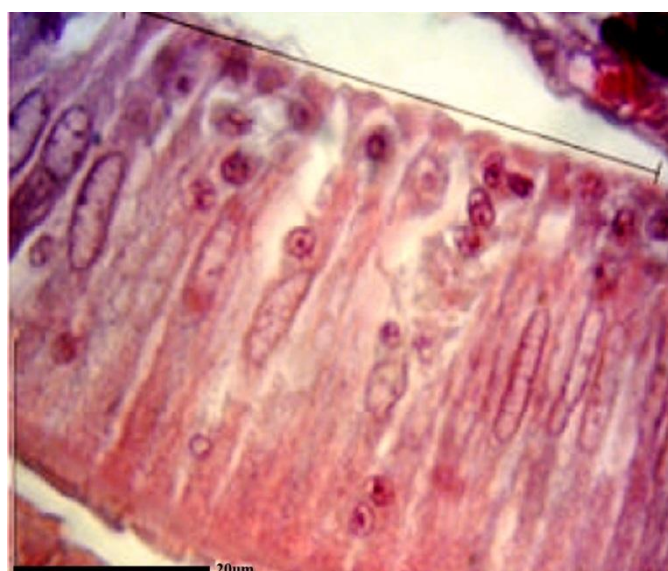


Figure 6. Lymphocyte, arrow demonstrate IELs($\times 7250$)

Discussion

The gut mucosa could be considered as a selective barrier to nutrients, that also inhibits pathogen and toxins (Murry et al. 1994).

Although there are many differences in the tissue structure of gut among teleost at microscopic level, the intestinal wall in *E. lucius*, comprised of the four layers like other vertebrates (Kumar & Tembhre 1996). According to the results, the gut mucosa in *E. lucius* had many folds coated with simple columnar epithelial cell and goblet cells. These results were in agreement with those reported in other fish species (Al-Abdulhadi (2005); Banan khojasteh et al. (2009); Hernandez et al. (2009)). In the present study, the number of goblet cells increased to the posterior part of intestine. Dai et al. (2007) has also reported the same result in rice field eel. They stated that this probably related to necessity of increased mucosal protection and lubrication for faecal exclusion.

Although, the mucus-secreting cells are a common feature of fish, the composition of mucus differs among species and even various portions of intestine (Reid et al. 1988). The mucus secreting cells with neutral glycoprotein compounds react positively to PAS, and those including acidic glycoproteins positively react to alcian blue (Raji & Norouzi 2010). The results of the present study showed that the intestinal goblet cells in *E. lucius* contain mix acidic and neutral glycoproteins, because of the positive reaction to PAS and alcian blue, simultaneously. The same results have been reported in northern pike and European catfish

(Cinar & Senol 2006). Neutral mucus combine with alkaline phosphatase involve in food emulsification in vertebrates. Acidic mucus act in protection of the intestinal epithelium against the glycosidase enzymes (Carrasson et al. 2006).

In the present study, tubular glands were not found in the intestinal mucosa of *E. Lucius*. Stoskopf (1993) also didn't detect these glands in the intestinal mucosa of codfish. The pattern of muscularis layers followed evenly the pattern of intestine mucosal folds. The tunica muscularis composed of two layers of smooth muscle in *E. Lucius*: outer longitudinal and thicker inner circular layers. Same muscle structures reported in *Rhamdia quelen*, Tilapia and *Ambassis sp.* (Martin & Blaber (1984); Hernandez et al. (2009)).

In the last decades mucosal immunology of more developed vertebrates is extremely reviewed, however, only little information is about this system in fish (Rombout et al. 2010) and in those that have been studied; no accumulations of leucocytes have been reported (Temkin & McMillan 1986). Large accumulation were located in the lamina propria and consisted of aggregations of Lymphocytes together with granulocytes, macrophages and plasma cells. Large accumulations also have been reported in *Oreochromis mossambicus* (Doggett & Harris 1991).

The GALT in *E. lucius* mainly consisted of diffuse populations of leucocytes in the epithelium and lamina propria and individual

leucocytes placed in the gut epithelium. According to the results, IELs significantly increased to the posterior part of intestine. The same result was also reported in *Barbus sharpeyi* (Nikbakht et al. 2007) and in sea bass *Dicentrarchus labrax* (L.) (Piccheietti et al. 1997). However, no significant difference was observed in IELs crowdedness along the intestine of *Cyprinus carpio* (Rombout et al. 1993b).

Intraepithelial lymphocytes present in the gut epithelium probably have important roles in epithelial protection from pathogens (Abelli et al. 1997). The lymphocytes located in the basal part of the epithelium included the majority of the IELs. A similar feature was identified in the intestine of the sea bass *Dicentrarchus labrax* (Abelli et al. 1997).

However, plasma cells, not abundant in number, were recognized as similar as those in mammalian and other teleost (Rombout et al. 1993b). In most teleost species studied, a layer called stratum granulosum consisting of one or a few rows of mast cells / eosinophilic granule cell is located in lamina propria submucosa (Reite 1997), as observed in the present study. As far as present knowledge goes, the main characteristics of mast cells / eosinophilic granule cell in teleost are quite identical to those of mast cells in mammals, except that some of the chemical materials of the mammalian mast cell, such as histamine, are replaced with others that have effects in teleost same as those of mast cell in mammals (Reite & Evensen 2006).

In conclusion, all cells necessary for a local or mucosal immune response appear to be present in the intestinal mucosa of *E. lucius*. In

addition, high amounts of mucus-secreting cells demonstrated in gut of *E. lucius*, possibly having a significant defense function.

Acknowledgements

This work was supported by the Iran National Science Foundation (INSF) within the framework of research [90001912].

References

- Abelli L., Picchietti S., Romano N., Mastrolia L., Scapigliati G. (1997) Immunohistochemistry of gut-associated lymphoid tissue of the sea bass *Dicentrarchus labrax* (L.). *Fish and Shellfish Immunology* 7, 235-245.
- Al-Abdulhadi H.A. (2005) Some comparative histological studies on alimentary tract of tilapia fish (*Tilapia spiluru*) and sea bream (*Mylio cuveir*). *Egyptian Journal of Aquatic Research* 31, 387-397.
- Banan khojasteh S.M., Sheikhzadeh F., Mohammanejad D., Azami A. (2009) Histological, histochemical and ultrastructural study of the intestine of Rainbow Trout (*Oncorhynchus mykiss*). *World Applied Science* 6(11), 1529-1531.
- Brandtzaeg P., Pabst R. (2004) Let's go mucosal: communication on slippery ground. *Trends in Immunology* 25, 570-577.
- Brandtzaeg P., Kiyono H., Pabst R., Russell M.W. (2008) Terminology: nomenclature of mucosa-associated lymphoid tissue. *Mucosal Immunology* 31.

- Carrasson M., Grau A., Dopazo L.R., Crespo S. (2006) A histological, histochemical and ultrastructural study of the digestive tract of *Dentex dentex* (pisces, sparidae). *Histology and Histopathology* 21(6), 579-593.
- Cerutti A. (2008) The regulation of IgA class switching. *Nature Reviews Immunology* 434.
- Cheroutre H., Madakamutil L. (2005) Mucosal effector memory T cells: the other side of the coin. *Cellular and Molecular Life Sciences* 62, 2853-2866.
- Cinar K., Senol N. (2006) Histological and histochemical characterization of the mucosa of the digestive tract in flower fish (*Pseudophoxinus antalyae*). *Anatomia, Histologia, Embryologia* 35, 147-151.
- Dai X., Shu M., Fang W. (2007) Histological and ultrastructural study of the digestive tract of rice field eel, *Monopoterus albus*. *Applied Ichthyology* 23, 177-183.
- Doggett T.A., Harris J.E. (1991) Morphology of the gut associated lymphoid tissue of *Oreochromis mossambicus* and its role in antigen absorption. *Fish and Shellfish Immunology* 1, 213-227.
- Hernandez D.R., Pérez Ganeselli M., Domitrovic M. (2009) Morphology, Histology and Histochemistry of the Digestive System of South American Catfish (*Rhamdia quelen*). *International Journal of Morphology* 7, 5-111.
- Kucharzik T., Luger N., Rautenberg K., Luger A., Schmidt M.A., Stoll R., Domschke W. (2000) Role of M cells in intestinal barrier function. *Annals of the New York Academy Science* 915, 171-183.
- Kumar S., Tembhre M. (1996) Anatomy physiology of fishes. 1st Edn. Nehru Nagar, Ghaziabad, Vikas Publishing House PVT Ltd, 70.
- Martin T.J., Blaber S.J.M. (1984) Morphology and histology of the alimentary tracts of *Ambassidae* (Cuvier) (Teleostei) in relation to feeding. *Morphology* 182, 295-305.
- Murry H.M., Wright G.M., Goff G.P. (1994) A comparative histological and histochemical study of the stomach from three species of pleuronectid, the Atlantic halibut, *Hippoglossus hippoglossus*, the yellowtail flounder, *Pleuronectes americanus*. *Canadian Journal of Zoology* 72, 1199-1210.
- Nikbakht M., Albughobeysh N., Peyghan R. (2007) Histological and Histometerical study of Gut Associated Lymphoid Tissue of intestinal bulb and proper intestine in *Barbus sharpeyi*. *Science Journal of Shahid Chamran University* 17, 106-116.
- Piccheietti S., Terribili F.R., Mastrolia L., Scapigliati G., Abelli L. (1997) Expression of lymphocyte antigenic developing Gut – Associated Lymphoid Tissue the sea bass (*Dicentrarchus Labrax* L.). *Anatomy and Embryology* 196(6), 457-463.
- Raji A.R., Norouzi E. (2010) Histological and histochemical study on the alimentary canal in Walking catfish (*Claris batrachus*) and piranha

(*Serrasalmus nattereri*). *Iranian Journal of Veterinary Research* 11(3), 255-261.

Reid P.E., Volz D., Cho K.Y., Owen D.A. (1988) A new method for the demonstration of oacy sugar in human colonic histochemical epithelial glycoproteins. *Histochemical Journal* 20, 510-518.

Reite O.B. (1997) The rodlet cells of teleosts: evidence of activation in tissues exposed to noxious agents. In: Abstracts of the 8th Conference of the European Association of Fish Pathologists, Edinburgh, 12.

Reite O.B., Evensen O. (2006) Inflammatory cells of teleostean fish: A review focusing on mast cells/eosinophilic granule cells and rodlet cells. *Fish and Shellfish Immunology* 20, 192-208.

Rombout J.H.W.M., Taverne N., Van de Kamp M., Taverne-Thiele A.J. (1993a) Differences in

mucus and serum immunoglobulin of carp (*Cyprinus carpio* L.). *Developmental and Comparative Immunology* 17, 309-317.

Rombout J.H.W.M., Taverne-thiele A.J., Villena M.L. (1993b) The Gut- Associated Lymphoid Tissue (GALT) of carp (*Cyprinus carpio* L.): An immunocytochemical analysis. *Developmental and Comparative Immunology* 17, 55-66.

Rombout J.H.W.M., Abelli L., Picchiatti S., Scapigliati G., Kiron V. (2010) Teleost intestinal immunology, *Fish and Shellfish Immunology* 32, 1-11.

Stoskopf M.K. (1993) Fish medicine. Saunders Company, 13.

Temkin R.J., McMillan D.B. (1986) Gut associated lymphoid tissue (GALT) of goldfish *Carassius auratus*. *Journal of Morphology* 190, 9-26.

تشریح ساختار بافتی روده و بافت لنفوئیدی ضمیمه روده در اردک ماهی *Esox* *Lucius* تالاب انزلی

نگین سلامات

گروه زیست شناسی دریا، دانشکده علوم دریایی و اقیانوسی، دانشگاه علوم و فنون دریایی خرمشهر، خرمشهر، ایران

چکیده

مطالعه بافتی روده ماهیان با افزایش تمایل به آبی پروری، افزایش یافته است، چراکه نیاز به اطلاعات بیشتری در ارتباط با تغذیه ماهیان می باشد. تحقیق حاضر با هدف تشریح ساختار بافتی و ویژگیهای هیستومتریک روده و بافت لنفوئیدی ضمیمه آن (*Esox lucius*) در اردک ماهی تالاب انزلی صورت گرفت. ۲۰ قطعه اردک ماهی از بندر انزلی جمع آوری شد. نمونه‌های بافتی از بخش‌های قدامی، میانی و خلفی روده اخذ و در محلول ثبوت بوئن تثبیت گردید. اسلایدهای بافتی جهت مطالعات بافت شناسی تهیه و با استفاده از رنگ آمیزی هماتوکسیلین-اؤزین، پریودیک اسید شیف و آلسیان بلو - پریودیک اسید شیف رنگ آمیزی شد. سطح مخاطی روده در این ماهی دارای چین های فراوان پوشیده شده با سلول های استوانه ای ساده و سلول های جامی بود که به هر سه روش رنگ آمیزی پاسخ مثبت داد. بنابراین به نظر می رسد موکوس ترشح شده از سلول های جامی روده در این ماهی از حاوی مخلوطی از گلیکوپروتئین های اسیدی و خنثی است. سلول های ائوزینوفیلی دانه دار در پارین روده مشاهده شدند. GALT در سراسر روده به شکل سلول های منفرد و یا تجمعات کوچک سلولی هم در بافت پوششی روده و هم در پارین مشاهده شد. لنفوسیتها، پلازما سل ها، سلول های دانه دار و ماکروفاژها در مخاط، پارین و زیرمخاط روده اردک ماهی مشاهده شدند. افزایش معنی دار تعداد لنفوسیتها به سمت روده خلفی حاوی تجمعات لنفوسیتی فراوان مشاهده شد.

کلمات کلیدی: روده، بافت لنفوئیدی ضمیمه روده، اردک ماهی، بافت شناسی، تالاب انزلی

نویسنده مسئول: salamatnegin@yahoo.com