Research Article

Determination of median lethal concentration (LC_{50}) and histopathological effects of malachite green on *Oncorhynchus mykiss*

M. Heydari[1], Z. Yaghoobi[2], S. Hosseini[3*], J. Mahdavi[4], A. Movahedinia[5], Z. Amini[6], S. Rouzbehani[7]

[1]Department of Aquatic Animal Health, Faculty of Veterinary Medicine, University of Tehran, Tehran, Iran, and Department of Pharmacognosy, Faculty of Pharmacy, Mazandaran University of Medical Sciences, Sari, Iran

[2]Department of Environmental Sciences, Faculty of Natural Resources and Marine Sciences, Tarbiat Modares University, Noor, Mazandaran, Iran

[3]Department of Biology, School of Science, Alzahra University, Tehran, Iran

[4]Expert of Shahid Motahary Cold Water Fishes Genetic and Breeding Research Center, Yasooj, Iran

[5]Department of Marine Biology, Faculty of Marine Sciences, University of Mazandaran, Babolsar, Iran

[6]Department of Marine Biology, Faculty of Marine Science, Khorramshahr University of Marine Science and Technology, Khorramshahr, Iran

[7]Graduated from Faculty of Biology Science, Shahid Beheshti University, Tehran, Iran

Received: April 2022 **Accepted:** August 2022

Abstract

The purpose of this study was to determine the lethal concentration (LC_{50}-96 h) of malachite green on rainbow trout and also the histology effects of this substance on the liver, gills and kidney. With increasing concentrations of malachite green, rainbow trout mortality increased during the period of 24 to 96 hours. Twenty four hour lethal concentration (LC_{50}-24 h) of malachite green on *O. mykiss* is 32.28 mg L^{-1}. Forty eight hour lethal concentration (LC_{50}-48 h) of malachite green is 16.32 mg L^{-1}, and 72-hour lethal concentration (LC_{50}-72 h) of malachite green is 2.52 mg L^{-1}. All lethal concentrations at 72 hours showed a clear reduction compared to 24 and 48 hours. The median lethal concentration of malachite green (LC_{50}-96 h) of rainbow trout was 0.83 mg L^{-1} during four consecutive days (96 hours). On the other hand, malachite green showed destructive effects on liver, gills and kidney tissue of rainbow trout, and these changes were more intense with increasing concentration of malachite green. Therefore, due to the grading of toxicity is determined by the amount of LC_{50}-96 h and also observing tissue effects exposed to this substance, the malachite green is considered highly toxic to rainbow trout. For this reason, there are always concerns about the possibility of its transmission to consumers or humans; therefore, regarding to this matter that using this substance in the fish farms has been prohibited by Iran Veterinary Organization, it is necessary to remove malachite green from the list of drugs used in fish breeding and provide the other safe drugs.

***Corresponding author's email:** saba.hoseyny@gmail.com.

Keywords: Malachite Green, Median Lethal Concentration, Histopathology, *Oncorhynchus mykiss*

[Downloaded from ijaah.ir on 2024-10-12]

[DOI: 10.52547/ijaah.8.1.41]

Introduction

There is no doubt that the disease is a first-class problem that affects the economic and long-term sustainability of the aquaculture industry; therefore, if the fish farming industry wants to continue its growth and dynamism, they should pay special attention to disease control (D'Agaro *et al*., 2022, Maldonado-Miranda *et al*., 2022, Easwaran *et al*., 2022). The basis of proper management is the proper use of chemicals to reduce or eliminate pathogens. Chemicals, drugs and agents that inhibit the growth of microbes and fungi are substances that are used more every day to repel pathogens, as a result of which their effects and consequences also increase in the long term (Hajam *et al*., 2022, Gatlin III and Yamamoto, 2022). Following the transfer of these chemicals to aquatic environments, some of these substances are absorbed by their bodies through water and the living environment of aquatic animals and enter the human food chain by depositing in their body tissues and in the future, it will cause failure in the metabolism of the human body and other organisms dependent on the water ecosystem (Gatlin III and Yamamoto, 2022).

During the past years (since 1936), malachite green has been used as an effective disinfectant to control and treat fungal diseases, skin diseases, protozoal and parasitic infections in tropical and subtropical fish (Hidayah *et al*., 2013, Jiang *et al*., 2015). The importance of malachite green reached its peak when it was recognized as a controller of Volgania sapper fungus (Sudova *et al*., 2007) and also salmon kidney infections. It should be noted that in 2000, due to reports of carcinogenic, mutagenic and teratogenic effects, the use of this substance as a drug in the aquaculture industry was banned by the US Food and Drug Administration (FDA) (Dong *et al*., 2014). Also, in some countries, aquatic animals should not be caught and consumed for at least 6 months after consuming malachite green. In Iran, the use of malachite green is prohibited in all stages of reproduction and breeding of aquatic animals. Unfortunately, reasons such as ease of access and low price have caused this substance to continue to be used illegally in the aquaculture industry (Sudova *et al*., 2007, Alderman, 1985). This issue requires strict and decisive supervision of the relevant organizations; because malachite green is very toxic and its residues cause respiratory poisoning, mutation and carcinogenesis in aquatic animals due to long-term persistence in aquatic body tissues like liver, gill and kidney (Jiang *et al*., 2009, El-Neweshy and Srag, 2011a) .

Studies have shown that the main and most objective effect of malachite green in fish and aquaculture is the effects of this substance in inhibiting the mitochondrial thiol-containing respiratory enzyme, which is why it is referred to as a respiratory poison that causes respiratory disorders and suffocation (Aerssens *et al*., 2022). Therefore, it is expected that after chronic exposure to malachite green, serious damage will be done to the gill tissue of fish. Liver and kidney are

[Downloaded from ijaah.ir on 2024-10-12]

[DOI: 10.52547/ijaah.8.1.41]

the chief metabolic and detoxification organs in vertebrates and they are highly susceptible to metabolic disturbances and a variety of toxicants to which the animal is exposed (Farhadian *et al*., 2022). Results of controlled exposure of fishes in the laboratory to toxicants such as pesticides and related chemicals suggest that liver is the organ in which the highest residues of such toxicants accumulate and it is this organ that suffers the greatest damage among other organs. So, fish is concerned as an appropriate animal to assess aquatic toxicity because of its ecological and economic importance and many species of fish are used for toxicity studies (Bhagat *et al*., 2021, Jolly *et al*., 2022, Töre *et al*., 2021) Selecting a species for these experiments depends on the availability of species, ease of breeding and ease of transportation (Embry *et al*., 2010). Rainbow trout, *Oncorhynchus mykiss*, is used as a model in this study (Hardy, 2002, Cho and Cowey, 2017).

This study aimed to determine the lethal concentration of malachite green (LC_{50} 96h) on rainbow trout and investigate histopathological effects on vital tissues such as liver, gills and kidney.

Materials and Methods

The experiment done in Shahid Motahary Cold Water Fishes Genetic and Breeding Research Center, Yasooj, Iran for this purpose, fifty *O. mykiss* are kept in the tanks for a week to adapt to the environmental conditions. The proper aeration and feeding (daily 2% of body weight) were conducted during this period.

The primary test was performed for finding the range of fatal of malachite green on *O. mykiss*, that the lethality of malachite green was obtained between 0.1 - 100 mg L^{-1} on this species. Acute toxicity test was carried out by using a stationary (static) technique and based on the standard instruction of the Organization of Economic Cooperation and Development (OECD) (TRC, 1984) on the *O. mykiss* for 96 hours (Van Heerden and Steyn, 1995).

Feeding of the fish was stopped 24 hours before the beginning of the acute toxicity test to obtain stable conditions (Banaei *et al*., 2008; Belanger *et al*., 2010).Water physicochemical parameters including pH (using a digital pH meter by the company HI-98128, Hanna), dissolved oxygen (oxygen meter by the HI-3810, Hanna) and temperature were recorded daily (Table 1).

Table 1. The amounts of physicochemical parameters of water used during the experiment

Parameter	Amount
Temperature (° C)	11.25 ± 0.82
pH	7.60 ± 0.46
Oxygen (mg L^{-1})	6.80± 0.87

After determination of the lethal range, the final acute toxicity test of malachite green on *O. mykiss* was performed in four treatments (concentrations of 0.1, 1, 10 and 100 mg L^{-1} and control group). In each treatment, thirty fish were placed into a 60-liter aquarium that had already been aerated. Dead fish were collected from the aquariums as soon as being seen and the mortality was recorded at 24 h, 48 h, 72 h and 96 h. After the completion of the test, acute

[Downloaded from ijaah.ir on 2024-10-12]

[DOI: 10.52547/ijaah.8.1.41]

toxicity test data were analyzed by using the Statistical Analysis Probit Method with a 95 percent confidence level.

To do histopathology tests, samples from the liver, gills and kidney of rainbow trout were prepared. First, the samples were fixed in 10% buffer formalin for a week and then were transferred to 70% ethanol. Other conventional procedures for histological examination were conducted using Histokinette (Tissue Tek Rotary, RX-11B, Japan). Then, the samples were moulded using Lockhart templates. Trimming was done by rotary microtome (Model Leica-2245) and five micrometer sections were prepared. The slides were stained with hematoxylin and eosin and analyzes were done using an optical microscope (Olympus) with different magnifications. Proper images were prepared and saved by a camera mounted on the microscope (Dinolight Digital Microscope) and the computer system connected to the camera is equipped with Dino Capture Software. Finally, the results of pathology and histopathological changes in tissues were evaluated (Srivastava *et al*., 2004).

Results

Toxicity test

During the experiment, physicochemical parameters such as pH, temperature and dissolved oxygen were measured and recorded daily (Table 1). The lethality of malachite green is estimated at 0.1 - 100 mg L^{-1} on *O. mykiss*. Rainbow trout mortality is enhanced with increasing concentrations of malachite green during 24 to 96 hours. After determining the lethality of malachite green in *O. mykiss*, an acute toxicity test (LC_{50}) was carried out at five different concentrations (control, 0.1, 1, 10, 100 mg L^{-1}) and the results of mortalities were measured during times of 24, 48, 72 and 96 hours (Table 2).

Table 2. Mortality of *O. mykiss* in acute toxicity test of malachite green (number of fish in each treatment = 30)

Concentration (mg L^{-1})	24-hour	48-hour	72-hour	96-hour
Control	0	0	1	1
0.1	7	9	12	15
1	16	18	22	26
10	19	23	25	29
100	24	27	30	30

After 24 hours, the number of mortality was achieved at concentrations of 0, 0.1, 1, 10 and 100 mg L^{-1} at 0, 7, 16, 19 and twenty four hours, respectively. Based on these results, lethal concentration (LC_{50}-24 h) of malachite green on *O. mykiss* (32.28 mg L^{-1}) was obtained during 24 hours (Table 3). Accordingly, the 48-hour lethal concentration (LC_{50}-48 h) of malachite green is 16.32 mg L^{-1}, which the amount of LC_{50}-48 h reduced compared with LC_{50}-24 h (32.28 mg L^{-1}). Other amounts of LC (LC_{50}-48 h) are presented in Table 4. After seventy two hours, the number of mortality reached 1, 12, 22, 25 and 30 at concentrations of 0, 0.1, 1, 10 and 100 mg L^{-1}, respectively. Accordingly, the 72-hour lethal concentration (LC_{50}-72 h) of malachite green is 2.52 mg L^{-1}. As seen, all lethal concentrations at 72 hours compared to 24 and 48 hours show a significant reduction. Other amounts of LC (LC_{50}-72 h) are presented in Table 5.

[Downloaded from ijaah.ir on 2024-10-12]

[DOI: 10.52547/ijaah.8.1.41]

Table 3. Lethal concentration (LC_{50}-95) of malachite green on *O. mykiss* during 24 hours

LC-24 h	Lethal concentration
LC_5	-87.02
LC_{10}	-60.67
LC_{20}	-28.76
LC_{30}	-5.75
LC_{40}	13.90
LC_{50}	32.28
LC_{60}	50.65
LC_{70}	70.31
LC_{80}	93.32
LC_{90}	125.23
LC_{95}	151.58

Table 4. Lethal concentration (LC_{50}-95) of malachite green on *O. mykiss* during 48 hours

LC-48 h	Lethal concentration
LC_5	-78.92
LC_{10}	-57.88
LC_{20}	-32.41
LC_{30}	-14.04
LC_{40}	1.65
LC_{50}	16.32
LC_{60}	30.99
LC_{70}	46.68
LC_{80}	65.05
LC_{90}	90.52
LC_{95}	111.56

Table 5. Lethal concentration (LC_{50-95}) of malachite green on *O. mykiss* during 72 hours

LC-72 h	Lethal concentration
LC_5	-8.78
LC_{10}	-6.28
LC_{20}	-3.25
LC_{30}	-1.07
LC_{40}	0.78
LC_{50}	2.52
LC_{60}	4.26
LC_{70}	6.13
LC_{80}	8.31
LC_{90}	11.33
LC_{95}	13.83

After 96 hours, the number of mortality was achieved at 1, 15, 26, 29 and 30 at concentrations of 0, 0.1, 1, 10 and 100 mg L^{-1}, respectively. Ninety six hour lethal concentration (LC_{50}-96 h) of malachite green is 0.83 mg L^{-1}. Other amounts of LC (LC_{50}-96 h) are presented in Table 6.

Table 6. Lethal concentration (LC_{50-95}) of malachite green on *O. mykiss* during 96 hours

LC-96 h	Lethal concentration
LC_5	-5.81
LC_{10}	-4.34
LC_{20}	-2.56
LC_{30}	-1.28
LC_{40}	-0.19
LC_{50}	0.83
LC_{60}	1.86
LC_{70}	2.95
LC_{80}	4.23
LC_{90}	6.01
LC_{95}	7.48

[Downloaded from ijaah.ir on 2024-10-12]

[DOI: 10.52547/ijaah.8.1.41]

The equation of the line is y = - 0.4496 x + 39.985, by establishing a correlation between the times of 24, 48, 72 and 96 h of exposure to malachite green and the LC_{50} mentioned in times. This equation can obtain the LC_{50} levels during different times because, in this equation, the R^2 is high and equal to 91% (Figure 1).

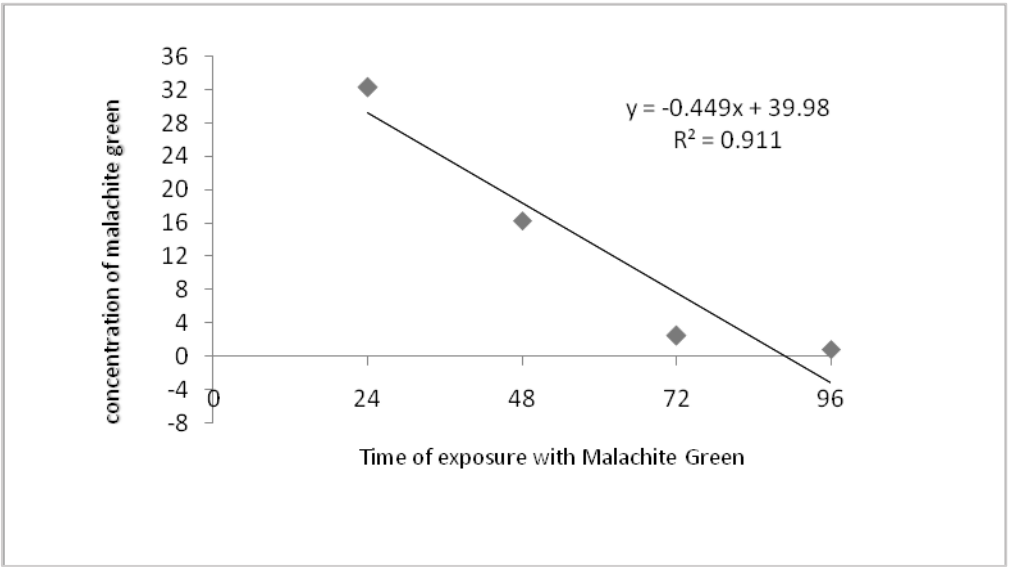

Figure 1. The graph of the relationship between times of exposure and different concentrations of malachite green.

Histopathology

Liver

In samples taken from the fish livers of the control group, histopathological lesions were not observed and had a normal liver structure. Hepatocytes with pink grainy cytoplasm and the central circular nucleus were multi-level cells that were consecutively lined from the center to the circumference of the lobule and created the liver plates. Sinusoids are irregular capillaries with vast space that continues from the center to the circumference in the form of bands between the cell plates and in their wall. In addition to the normal endothelial cells, there were a number of Kupffer cells that are responsible for blood purification. Disse space that separates the epithelium of the liver (hepatocytes) from the sinusoidal endothelium was also seen (Figure 2).

Various histopathological lesions in the liver of rainbow trout were observed at different concentrations of malachite green. Lesions such as bleeding and dilation of disse space were observed in the treatment of malachite green at a concentration of 0.1. Also in treatment 1, in addition to the mentioned lesions at concentrations of 0.1, lesions such as vacuolation and necrosis were observed. By increasing the concentration of malachite green to 10, lesions such as hyperemia and hemorrhage were observed with greater intensity, in addition, in treatment 100 also lesions such as vacuolation and lateral position of hepatocytes nucleus, were the most obvious lesions in the liver.

[Downloaded from ijaah.ir on 2024-10-12]

[DOI: 10.52547/ijaah.8.1.41]

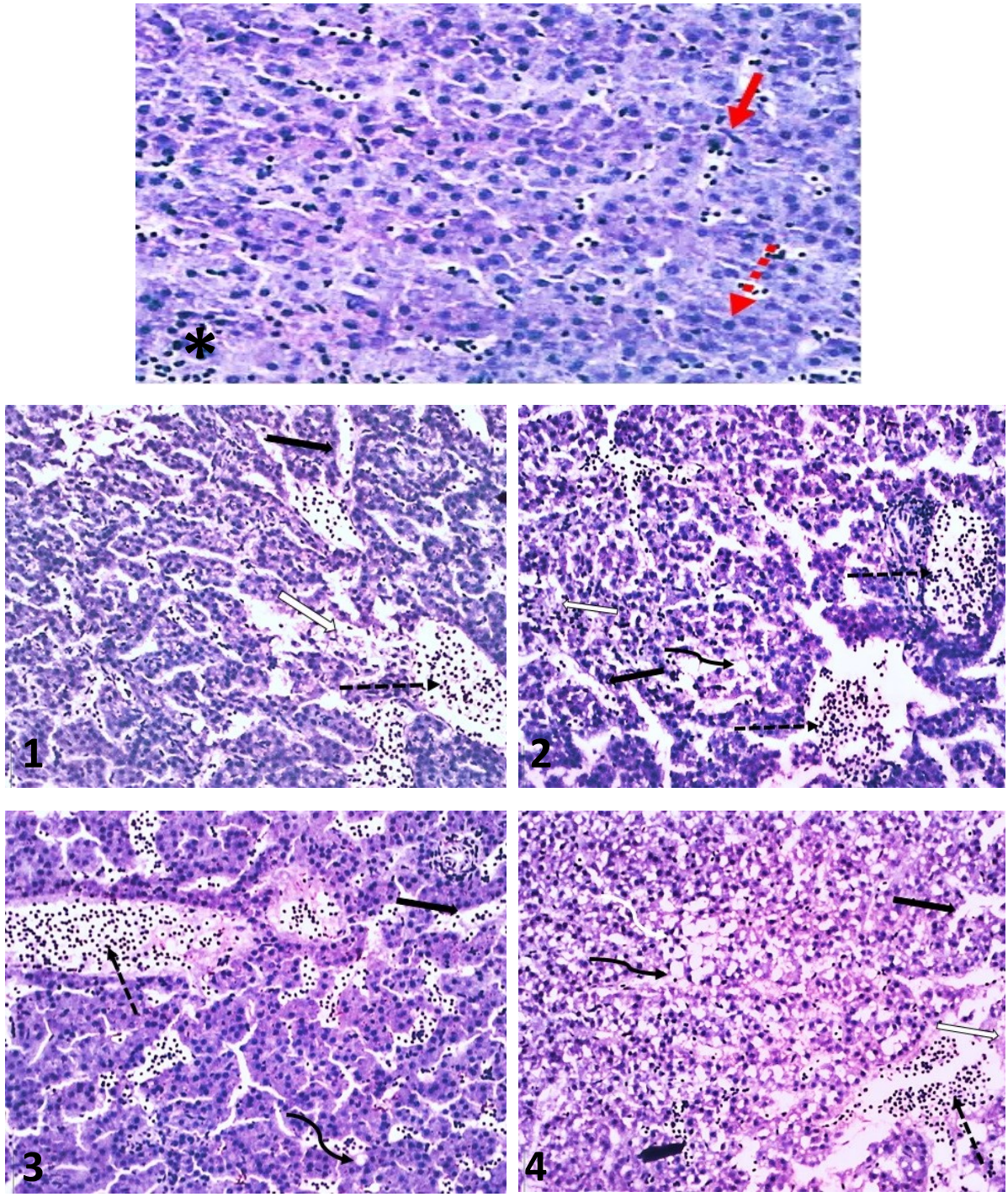

Figure 2. Tissue structure of rainbow trout normal liver in the control group (*). Sinusoid (red arrow), hepatocytes (cut red arrow) (H & E × 725). Optical microscopic images of liver tissue of rainbow trout exposed to malachite green at concentrations of 1: 0.1, 2:1, 3: 10 and 4: 100. Necrosis of liver cells (white arrow), dilation of space disse (black arrow), hemorrhage (cut black arrow), vacuolation (curved black arrow), the lateral position of hepatocytes nucleus (curved white arrow) (H & E × 725).

Gills

In samples taken from fish gills of the control group histopathological lesions were not observed and gills had a normal structure. Gill filaments were placed perpendicular to the gill arch and lamellae were observed perpendicular to the filaments (Figure 3).

Various histopathological lesions were observed in the gills of rainbow trout exposed to different concentrations of malachite

[Downloaded from ijaah.ir on 2024-10-12]

[DOI: 10.52547/ijaah.8.1.41]

green. The bulge of epithelium from the basement membrane, creating of edmatose space and clubbing of the end of lamellae were observed as the first changes in treatment 0.1. In addition to mentioned lesions, hyperplasia and vascular dilation were also visible in treatment 1. Mentioned lesions were observed with more intensity by increasing the concentration of malachite green to 10 and 100.

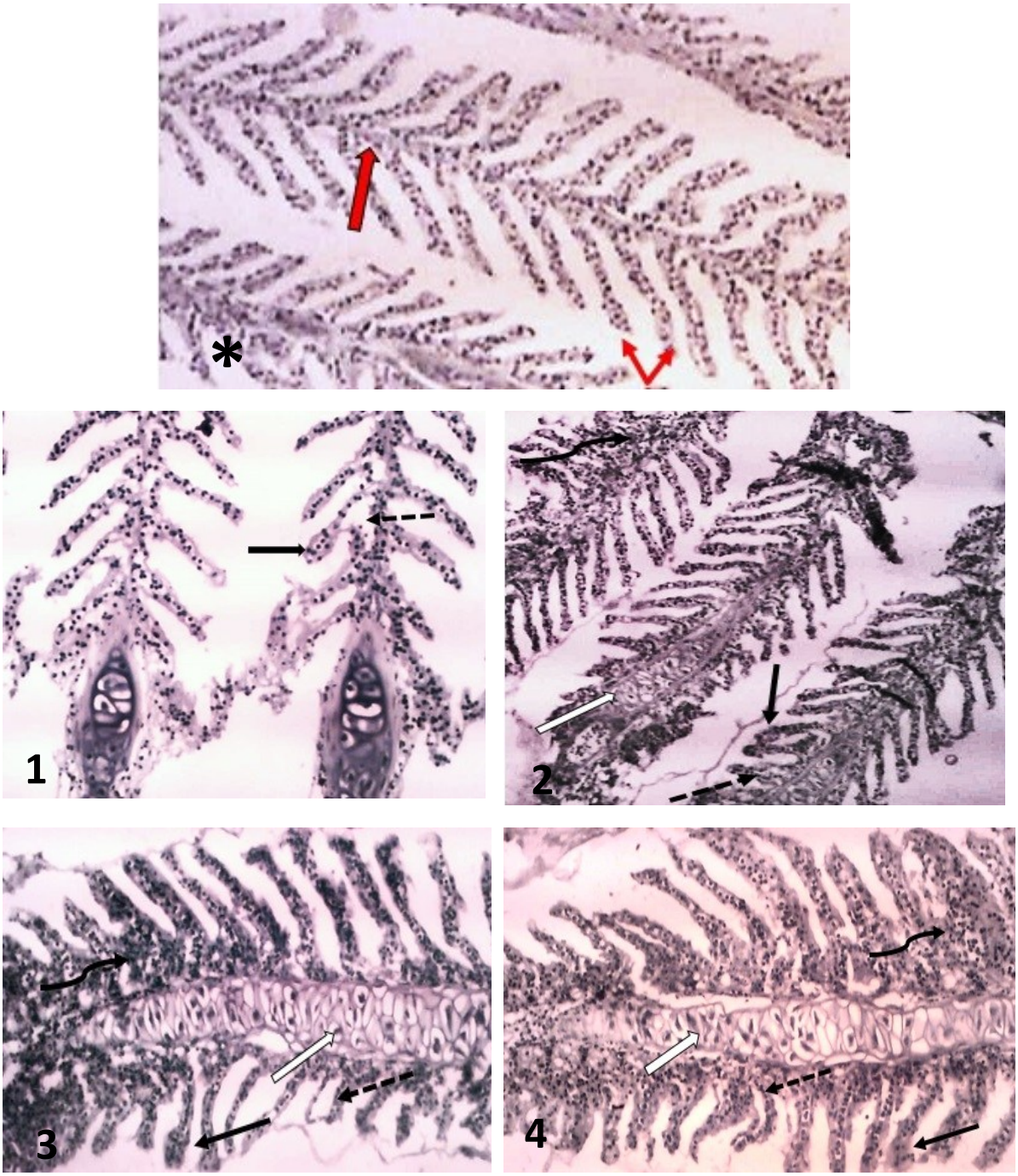

Figure 3. Normal structure of rainbow trout gills in the control group (*). The first gill filaments (red arrow), lamellae (red two heads arrow) (H & E × 725). Optical microscopic images of gills tissue of rainbow trout exposed to malachite green at concentrations of 1: 0.1, 2: 1, 3: 10 and 4: 100. The bulge of epithelium from the basement membrane and creating of edmatose space (cut black arrow), clubbing the end of lamellae (black arrow), hyperplasia (curved black arrow), vascular dilation (white arrow) (H & E × 725).

[Downloaded from ijaah.ir on 2024-10-12]

[DOI: 10.52547/ijaah.8.1.41]

Kidney

In samples taken from fish kidneys of the control group no histopathological lesions were observed and the structure of the kidney was normal. Renal corpuscle and urinary tubes with normal structures are placed among the connective tissue (Figure 4). Histopathological lesions in renal tissue of rainbow trout were observed at different concentrations of malachite green.

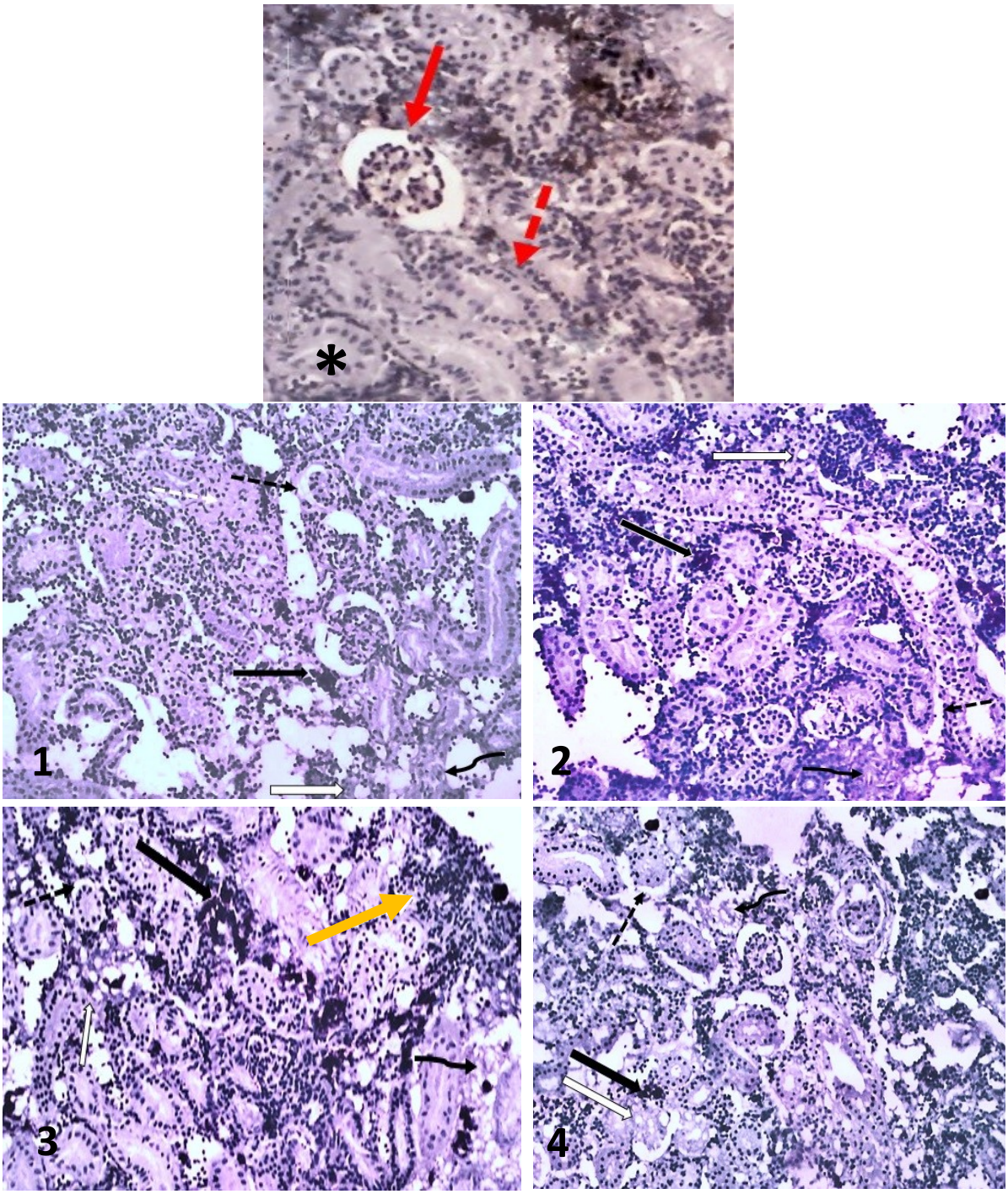

Figure 4. The structure of normal kidney tissue of rainbow trout in the control group (*). Renal corpuscle (red arrow), urinary tubes (cut red arrow) (H & E × 725). Optical microscopic images of kidney tissue of rainbow trout exposed to malachite green at concentrations of 1: 0.1, 2:1, 3: 10 and 4: 100. Melanomacrophage aggregations (black arrow), separation of the epithelium from the basement membrane (cut black arrow), renal tubular necrosis (curved black arrow), vacuolation (white arrow), hemorrhage (yellow arrow) (H & E × 725).

[Downloaded from ijaah.ir on 2024-10-12]

[DOI: 10.52547/ijaah.8.1.41]

Melanomacrophage aggregations, separation of the epithelium from the basement membrane, renal tubular necrosis and vacuolation are such lesions in the concentration of 0.1 malachite green. At higher concentrations of malachite green such as 1, 10 and 100 these lesions were visible with more intensity. In other words, by increasing the concentration of malachite green, the intensity of these changes also expands**.**

Discussion

It is important that appropriate medications use to control fungal diseases, in addition to having optimum performance, also have minimal toxic effects (Garg *et al*., 2020). Although malachite green has carcinogenic properties and its use is limited in some countries because of carcinogenesis and some environmental effects (Anokhina *et al*., 2021, Sun *et al*., 2021) but it has always been used by reproduction centers of fish, especially in Iran due to favorable impact in the prevention and treatment of fungal diseases (Alaboudi, 2022, Shahrani *et al*., 2021).

In this study, the toxicity of malachite green toxin along with its effect on clinical behaviors and tissue changes of *O. mykiss* were studied. During the 96 hours of all acute toxicity tests, except for 72 hours and 96 hours, no losses were observed in the control group. All chemical factors including pH, EC and hardness were suitable and controlled. The values of these factors did not change in any of the experiments due to the addition of malachite green to water. As the level of malachite green increased, rainbow trout mortality increased over the 24 - 96-hour period. Twenty four hour lethal concentration (LC_{50}-24 h) of malachite green on *O. mykiss* is 32.28mg L^{-1}. Fourty eight hour lethal concentration (LC_{50}-48 h) of malachite green is 16.32 mg L^{-1}, as can be seen, the LC_{50}-48 h decreased in comparison with the LC_{50}-24 h. Seventy two hour lethal concentration (LC_{50}-72 h) of malachite green is 2.52 mg L^{-1}. All lethal concentrations at 72 hours showed a significant reduction compared to 24 and 48 hours. The median lethal concentration of malachite green (LC_{50}-96 h) of *O. mykiss* was 0.83 mg L^{-1} during four consecutive days (96 hours). Due to the classification of toxicity which is determined by the amount of 96 h LC_{50}, malachite green is considered very toxic to *O. mykiss*. Moreover, in some cases, the accumulation of toxins in the tissues of fish can also increase the harmful impact on the fish body and within 96 hours of experiment leads to decreasing of LC_{50}. According to Table 6, the lethal concentration of malachite green was 0.83 during four consecutive days (96 hours) at 50% (LC_{50}-96 h). Considering that, the toxicity of materials is determined by using the LC_{50}-96 h. in this case, the toxicity of malachite green is too much for *O. mykiss* (Perez-Estrada *et al*., 2008).

Srivastava et al (1995) investigated the toxicity of malachite green on *Heteropneustes fossilis*, which is often used in fish farming. Exposure to malachite green at a concentration of 0.20 mg L^{-1} (15 th LC_{50} 96) for 96 h significantly decreased the biochemical parameters of fish blood serum. Short-term exposure (10-20 days) to subacute levels of 0.10 mg L^{-1} (110 th of 96-hour LC_{50}) and

[Downloaded from ijaah.ir on 2024-10-12]

[DOI: 10.52547/ijaah.8.1.41]

sublethal levels of 0.05 mg L^{-1} (120 th of 96-hour LC_{50}) of malachite green also resulted in significant reductions. These changes are caused by the exposure of the fish and causing stress and, as a result, damage to the internal organs.

Some toxins (such as malachite green and cyanide) cause clinical symptoms of respiratory failure by influencing on the cellular level of the respiratory system. In some cases, which toxins cause gill damage, oxygenating the water causes a decrease in respiratory failure, but it does not help when the gill damage is at the cellular level. (Krogdahl *et al*., 2022, Barot and Bahadur, 2013, Roberts and Palmeiro, 2008, Southgate and Branson, 2001). Pathological symptoms due to low water quality or gill parasites have intensified the impact of pesticides and made it difficult to diagnose (Krogdahl *et al*., 2022). When the fish are exposed to a constant concentration of the toxin over time, fish resistance is reduced and there is more opportunity to influence of toxin. Moreover, in some cases, the accumulation of toxins in the tissues of fish can also increase the harmful impact on the fish body and within 96 hours of experiment leads to decreasing of LC_{50}. 0.01 LC_{50}-96 h is recommended as a safe and secure level for aquatic animals which is equal to 0.008 mg L^{-1} in this study (Alderman and Clifton-Hadley, 1993).

Malachite green is toxic to the liver and is very stable that remains in the tissues for a long time (Sun *et al*., 2021). Also using it in the eggs leads to widespread deformities (congenital defects). Also, it leads to the incidence of extensive defects (birth defects) in eggs at the time of consumption (Sinha *et al*., 2021a, Pipoyan *et al*., 2020). It is a good anti-fungal and anti-ectoparasites, but it is also a toxin for the respiratory system, teratogen and carcinogen. Malachite green stays in the muscles for a long time and accumulates more with re-treatment. Malachite green toxicity is highly dependent on temperature and increases with a temperature rise. Its toxicity is higher in lower pH and it also is a plant toxin. This compound is inactivated by dose (oxidized) (Gul *et al*., 2021, Al-Yousef *et al*., 2021, Mao *et al*., 2021).

Malachite green is toxic to young larvae and eggs near hatching. Toxicity in fish is usually associated with respiratory failure (breathing disorder) (Novotny, 2021). According to the movements of the larvae before death, it seemed a state similar to hypoxia occurred, and oxygen recorded data also confirm this (Meinertz *et al*., 1995).

The fish liver is a very important organ for toxicology studies. The liver position and functions could be the main reason for the importance of this organ as a primary target organ in dealing with different types of contaminants and toxins (Sinha *et al*., 2020, Brusle and i Anadon, 2017). Histopathological study of rainbow trout liver exposed to different treatments of malachite green showed different signs of histopathological changes. Among the prominent tissue lesions in this study can be noted vacuolation of hepatocytes, haemorrhage, the nucleus in a lateral position and distention of disse space.

The intensity of these lesions increased with increasing the concentration of malachite

[Downloaded from ijaah.ir on 2024-10-12]

[DOI: 10.52547/ijaah.8.1.41]

green and in case of continuation of pollution, may be entered more severe injuries and damage to the liver and leads to liver dysfunction (Sinha *et al*., 2021a). A related study conducted by El-Neweshy and Srag in 2011, in addition to reports of liver tissue lesions in Nile tilapia similar to this study, expressed the amount of damage to the tissue and their extent in direct contact with the pollutant concentration (El-Neweshy and Srag, 2011a). Also, rainbow trout exposure to malachite green in addition to focal necrosis in the liver leads to damages such as congestion, damage to the mitochondria and nuclear changes (Shourbela *et al*., 2020). Hypertrophy, vacuolation and hepatic cirrhosis are reported as other lesions in the study by Srivastava et al. (1998) in *H. fossilis* exposed to malachite green. In addition to malachite green, other pesticides may also have similar effects on *Cirrhinus mrigala* (Ghayyur *et al*., 2021), Carp, *Cyprinus carpio* (Shivalingu and Jayabhaye, 2021), *Clarias gariepinus* (Islam *et al*., 2021).

Gill is an external organ. The epithelium and its direct connection to the surrounding environment is considered primary target organs for pollutants. Long-term exposure to pollutant leads to their absorption through the gills and create gill damage and histopathological effects. Hence this organ in fish can be a useful indicator for the evaluation of water quality (Alaguprathana *anf* Poonkothai**,** 2021). The results of this study showed clear histopathological changes in the gills of rainbow trout exposed to different concentrations of malachite green. Changes such as the bulging epithelium from the basement membrane, creating space for edmatozation, clubbing the end of lamellae, hyperplasia and vessel dilation were the most common effects observed in this study. Many of these effects have been observed in the gills are kind of defense mechanisms against the entry of contaminants into the body (Sharma *et al*., 2021). The bulging of epithelium, creating edema space, increasing the number of goblet cells and enhancing the secretion of mucus are defense mechanisms which usually lead to an increase in the space between the water and the blood and act as a barrier against contaminants (Sinha *et al*., 2021b). However, these effects due to the increased gas emission distance between water and blood and decreased contact area reduced gas exchange in organisms (Mohamad *et al*., 2021). Hyperplasia like the edema in fish gills is one of the defensive reactions against contaminants that reduce the level of respiratory surface and increase the emission distance of contaminant–blood (Sinha *et al*., 2021b, Shukla *et al*., 2020). A same study examined the effect of malachite green on the gill tissue of Nile tilapia. Hyperplasia, the fusion of the lamellae and necrosis were significant side effects observed in this study, which is fully confirmed the results of the present study (El-Neweshy and Srag, 2011b). The impact of malachite green on *Cyprinus carpio* (Sinha *et al*., 2021b), *Carassius auratus* (Yadav and Singh, 2011) have also been studied. Separation of the epithelium from basement membrane, hemorrhage, leukocyte penetration and necrosis were the side effects that have been observed in these studies. Several studies have shown the similar effects

[Downloaded from ijaah.ir on 2024-10-12]

[DOI: 10.52547/ijaah.8.1.41]

of other pesticides on the fish gills (Ghayyur *et al*., 2021, Islam *et al*., 2021, Viana *et al*., 2021b).

Kidney is a vital organ of the body and one of its most important functions is to regulate and maintain homeostasis in the body (Li *et al*., 2020). Contaminants are initially absorbed in fish liver and then excreted through the kidney. Accordingly, the kidney is one of the first organs that is exposed to environmental contaminants and is impressed (Ghribi *et al*., 2019). The histopathological results of rainbow trout kidney exposed to different concentrations of malachite green showed lesions such as melanomacrophages aggregation, separation of the epithelium from the basement membrane, obstruction or reducing the space of lumen, renal tubular necrosis, hemorrhage and vacuolation. The formation of melanomacrophage centers is such observed lesions in this study that contains melanin and shows defense mechanism of the kidney against external factors. These centers are not considered the serious lesions, however, their beneficial and effective presence has been known and many researchers consider melanomacrophage centers as non-specific cytologic biomarkers caused by pollution and environmental degradation (Durai *et al*., 2021, Viana *et al*., 2021a). Vacuolation of cytoplasm in epithelial cells of the renal tubules shows the compatibility of the host cells to prevent damage and destruction caused by a pollutant. Glomerular contraction, separation of the epithelium from the basement membrane, vacuolation and necrosis of the urinary tubules are reported as lesions in fish exposed to malachite green in the study by Srivastava et al (1998). Another study examined the impact of malachite green in Nile tilapia and lesions such as degeneration of the renal tubules and tubular necrosis are the most common symptoms observed in this study (El-Neweshy and Srag, 2011b). It seems that in addition to malachite green, other pesticides such as diazinon (Banaee *et al*., 2013), captan (Boran *et al*., 2012) and butachlor (Ahmadivand *et al*., 2014) also have the same results on rainbow trout.

Generally, in chronic pollution conditions, histopathological changes observed in this study may be far greater and cause severe physiological disorders and ultimately leading to the death of the fish.

According to the results of this study, malachite green is considered highly toxic to *O. mykiss*. Harmful effects of malachite green on the liver, kidney and gill tissues of rainbow trout are quite evident and cause tissue changes in the mentioned organs. So, excessive use of this combination can affect fish health (Bills, 1974).

Today, the increasing number of pollutants used in industries, including malachite green, has become a challenging issue for researchers, so providing an effective solution to replace or remove these pollutants from the environment seems very necessary. Following the very adverse environmental effects of malachite green and the restriction of use by the many countries, it can be appropriate to use low-risk compounds as an alternative.

Acknowledgment

The authors are thankful to the Marine Science Faculty, Khorramshahr University of Marine

[Downloaded from ijaah.ir on 2024-10-12]

[DOI: 10.52547/ijaah.8.1.41]

Science and Technology, Khorramshahr, Khouzestan, Iran.

Conflicts of interest

Authors have no conflict of interest on this work.

References

Aerssens, D., Cadoni, E., Tack, L. and Madder, A., 2022. A Photosensitized Singlet Oxygen (1O2) Toolbox for Bio-Organic Applications: Tailoring 1O2 Generation for DNA and Protein Labelling, Targeting and Biosensing. *Molecules*, *27*(3), p.778. https://doi.org/10.3390/molecules27030778

Ahmadivand, S., Farahmand, H., Mirvaghefi, A.R., Eagderi, S., Shokrpoor, S. and Rahmati-Holasoo, H., 2014. Histopathological and haematological response of male rainbow trout (*Oncorhynchus mykiss*) subjected to butachlor. *Veterinarni Medicina*, *59*(9). https://doi.org/10.17221/7683-VETMED

Alaboudi, A.R., 2022. Chemical residues: potential food safety hazards in the Middle East. In *Food Safety in the Middle East* (pp. 143-186). Academic Press. https://doi.org/10.1016/B978-0-12-822417-5.00004-0

Alaguprathana, M. and Poonkothai, M., 2021. Haematological, biochemical, enzymological and histological responses of *Labeo rohita* exposed to methyl orange dye solution treated with Oedogonium subplagiostomum AP1. *Environmental Science and Pollution Research*, *28*(14), 17602-17612. https://doi.org/10.1007/s11356-020-12208-7

Alderman, D.J., 1985. Malachite green: a review. *Journal of fish diseases*, *8*(3), 289-298. https://doi.org/10.1111/j.1365-2761.1985.tb00945.x

Al-Yousef, H.A., Alotaibi, B. M., Alanazi, M.M., Aouaini, F., Sellaoui, L. and Bonilla-Petriciolet, A., 2021. Theoretical assessment of the adsorption mechanism of ibuprofen, ampicillin, orange G and malachite green on a biomass functionalized with plasma. *Journal of Environmental Chemical Engineering*, *9*(1), p.104950. https://doi.org/10.1016/j.jece.2020.104950

Anokhina, E.P., Tolkacheva, A.A. and Korneeva, O.S., 2021, February. Saprolegnosis: dissemination in aquaculture and control methods. In *IOP Conference Series: Earth and Environmental Science* (Vol. 640, No. 6, p. 062027). IOP Publishing. https://doi.org/10.1088/1755-1315/640/6/062027

Banaee, M., Sureda, A., Mirvaghefi, A.R. and Ahmadi, K., 2013. Biochemical and histological changes in the liver tissue of rainbow trout (*Oncorhynchus mykiss*) exposed to sub-lethal concentrations of diazinon. Fish physiology and biochemistry, 39(3), 489-501. https://doi.org/10.1007/s10695-012-9714-1

Banaei, M., MIR, V.A., Rafei, G.R. and Majazi, A.B., 2008. Effect of sub-lethal diazinon concentrations on blood plasma biochemistry, International Journal of Environmental Research. 2(2), 189-198.

[Downloaded from ijaah.ir on 2024-10-12]

[DOI: 10.52547/ijaah.8.1.41]

Barot, J. and Bahadur, A., 2013. Behavioural and histopathological effects of azod e on kidne and gills of *Labeo rohita* fingerlings. *Journal of Environmental Biology*, 34, 147-152.

Belfroid, A.C., Van Drunen, M., Beek, M.A., Schrap, S.M., Van Gestel, C.A.M. and Van Hattum, B., 1998. Relative risks of transformation products of pesticides for aquatic ecosystems. *Science of the Total Environment*, *222*(3), 167-183. https://doi.org/10.1016/S0048-9697(98)00298-8

Bhagat, J., Singh, N., Nishimura, N. and Shimada, Y., 2021. A comprehensive review on environmental toxicity of azole compounds to fish. *Chemosphere*, *262*, p.128335. https://doi.org/10.1016/j.chemosphere.2020.128335

BILLS, T. D., 1974. *Toxicity of formalin, malachite green, and the mixture to four life stages of rainbow trout.*

Boran, H., Capkin, E., Altinok, I. and Terzi, E., 2012. Assessment of acute toxicity and histopathology of the fungicide captan in rainbow trout. *Experimental and Toxicologic Pathology*, *64*(3), 175-179. https://doi.org/10.1016/j.etp.2010.08.003

Brusle, J. and i Anadon, G.G., 2017. The structure and function of fish liver. In *Fish morphology* (pp. 77-93). Routledge. https://doi.org/10.1201/9780203755990-6

Cho, C.Y. and Cowey, C.B., 2017. Rainbow trout, *Oncorhynchus mykiss*. In Handbook of nutrient requirements of finfish (pp. 131-144). CRC Press.

D'Agaro, E., Gibertoni, P. and Esposito, S., 2022. Recent Trends and Economic Aspects in the Rainbow Trout (*Oncorhynchus mykiss*) Sector. *Applied Sciences*, *12*(17), p. 8773. https://doi.org/10.3390/app12178773

Dong, J.X., Xu, C., Wang, H., Xiao, Z.L., Gee, S.J., Li, Z.F., Wang, F., Wu, W.J., Shen, Y.D., Yang, J.Y. and Sun, Y.M., 2014. Enhanced sensitive immunoassay: noncompetitive phage anti-immune complex assay for the determination of malachite green and leucomalachite green. *Journal of agricultural and food chemistry*, *62*(34), 8752-8758. https://doi.org/10.1021/jf5019824

Durai, U., Athisuyambulingam, M., Viswambaran, G. and Beevi, F.S.M., 2021. Cytopathological changes of Selected Tissues in Asian Sea Bass, Latescalcarifer (Bloch) Exposed to Mercury. *Annals of the Romanian Society for Cell Biology*, 1749-1772.

Easwaran, M., Raja, N., Eveline, D., Monford Paul Abishek, N., Ahn, J. and Shin, H.J., 2022. Future Therapeutic Approaches to Annihilate Bacterial Fish Diseases in Aquaculture. In *Aquaculture Science and Engineering* (pp. 463-495). Springer, Singapore. https://doi.org/10.1007/978-981-19-0817-0_17

El-Neweshy, M.S. and Srag, M.A.A., 2011. Chronic malachite green toxicity in Nile tilapia: Pathological and hematological studies with special reference to quantitative histopathological assessment. *Researcher*, *3*(4), 55-64.

[Downloaded from ijaah.ir on 2024-10-12]

[DOI: 10.52547/ijaah.8.1.41]

Embry, M.R., Belanger, S.E., Braunbeck, T.A., Galay-Burgos, M., Halder, M., Hinton, D.E., Léonard, M.A., Lillicrap, A., Norberg-King, T. and Whale, G., 2010. The fish embryo toxicity test as an animal alternative method in hazard and risk assessment and scientific research. *Aquatic toxicology*, *97*(2), 79-87. https://doi.org/10.1016/j.aquatox.2009.12.008

Farhadian, S., Hashemi-Shahraki, F., Asadpour, S., Shareghi, B., Shakerian, B., Rafatifard, M. and Firooz, A.R., 2022. Malachite Green, the hazardous materials that can bind to Apo-transferrin and change the iron transfer. *International Journal of Biological Macromolecules*, *194*, 790-799. https://doi.org/10.1016/j.ijbiomac.2021.11.126

Garg, A., Sharma, G.S., Goyal, A.K., Ghosh, G., Si, S.C. and Rath, G., 2020. Recent advances in topical carriers of anti-fungal agents. *Heliyon*, *6*(8), p.e04663. https://doi.org/10.1016/j.heliyon.2020.e04663

Gatlin III, D.M. and Yamamoto, F.Y., 2022. Nutritional supplements and fish health. In *Fish Nutrition* (pp. 745-773). Academic Press. https://doi.org/10.1016/B978-0-12-819587-1.00004-5

Ghayyur, S., Khan, M.F., Tabassum, S., Ahmad, M.S., Sajid, M., Badshah, K., Khan, M.A., Ghayyur, S., Khan, N.A., Ahmad, B. and Qamer, S., 2021. A comparative study on the effects of selected pesticides on hemato-biochemistry and tissue histology of freshwater fish *Cirrhinus mrigala* (Hamilton, 1822). *Saudi Journal of Biological Sciences*, *28*(1), 603-611. https://doi.org/10.1016/j.sjbs.2020.10.049

Ghribi, R., Correia, A.T., Elleuch, B. and Nunes, B., 2019. Testing the impact of contaminated sediments from the southeast marine coast of Tunisia on biota: a multibiomarker approach using the flatfish *Solea senegalensis*. *Environmental Science and Pollution Research*, *26*(29), 29704-29721. https://doi.org/10.1007/s11356-019-05872-x

Gul, K., Khan, H., Muhammad, N., Ara, B. and Zia, T.U.H., 2021. Removal of toxic malachite green dye from aqueous environment using reduced magnetic graphene oxide as an efficient and reusable adsorbent. *Separation Science and Technology*, *56*(15), 2507-2520. https://doi.org/10.1080/01496395.2020.1839498

Hajam, Y.A., Kumar, R., Rani, R. and Sharma, P., 2022. Efficacy of different treatments available against bacterial pathogens in fish. In *Bacterial Fish Diseases* (pp. 379-398). Academic Press. https://doi.org/10.1016/B978-0-323-85624-9.00013-0

Hardy, R.W., 2002. Rainbow trout, *Oncorhynchus mykiss*. *Nutrient requirements and feeding of finfish for aquaculture*, 184-202. https://doi.org/10.1079/9780851995199.0184

Hidayah, N., Bakar, F.A., Mahyudin, N.A., Faridah, S., Nur-Azura, M.S. and Zaman, M.Z., 2013. Detection of malachite green and leuco-malachite green in fishery industry. *International Food Research Journal*, *20*(4), 1511.

[Downloaded from ijaah.ir on 2024-10-12]

[DOI: 10.52547/ijaah.8.1.41]

Inyang, I.R., Daka, E.R. and Ogemba, E.N., 2010. Changes in electrophyte activites *Clarias gariepinus* exposed to diazinon. J. Trop. Biol. Environ. Sci. 7, 198-200.

Islam, M.A., Amin, S.N., Brown, C.L., Juraimi, A.S., Uddin, M.K. and Arshad, A., 2021. Determination of Median Lethal Concentration (LC_{50}) for Endosulfan, Heptachlor and Dieldrin Pesticides to African Catfish, *Clarias gariepinus* and Their Impact on Its Behavioral Patterns and Histopathological Responses. *Toxics*, *9*(12), p.340. https://doi.org/10.3390/toxics9120340

Jiang, Y., Chen, L., Hu, K., Yu, W., Yang, X. and Lu, L., 2015. Development of a fast ELISA for the specific detection of both leucomalachite green and malachite green. *Journal of Ocean University of China*, *14*(2), 340-344. https://doi.org/10.1007/s11802-015-2407-5

Jiang, Y., Xie, P. and Liang, G., 2009. Distribution and depuration of the potentially carcinogenic malachite green in tissues of three freshwater farmed Chinese fish with different food habits. *Aquaculture*, *288*(1-2), 1-6. https://doi.org/10.1016/j.aquaculture.2008.10.025

Jolly, Y.N., Rakib, M.R.J., Islam, M.S., Akter, S., Idris, A.M. and Phoungthong, K., 2022. Potential toxic elements in sediment and fishes of an important fish breeding river in Bangladesh: a preliminary study for ecological and health risks assessment. *Toxin reviews*, *41*(3), 945-958. https://doi.org/10.1080/15569543.2021.1965624

Krogdahl, Å., Kortner, T.M. and Hardy, R.W., 2022. Antinutrients and adventitious toxins. In *Fish Nutrition* (pp. 775-821). Academic Press. https://doi.org/10.1016/B978-0-12-819587-1.00001-X

Li, X., Zheng, S. and Wu, G., 2020. Amino acid metabolism in the kidneys: nutritional and physiological significance. *Amino Acids in Nutrition and Health*, 71-95. https://doi.org/10.1007/978-3-030-45328-2_5

Maldonado-Miranda, J.J., Castillo-Pérez, Lff. J., Ponce-Hernández, A. and Carranza-Álvarez, C., 2022. Summary of economic losses due to bacterial pathogens in aquaculture industry. In *Bacterial Fish Diseases* (pp. 399-417). Academic Press. https://doi.org/10.1016/B978-0-323-85624-9.00023-3

Mao, G., Wang, F., Wang, J., Chen, P., Zhang, X., Zhang, H., Wang, Z. and Song, A., 2021. A sustainable approach for degradation and detoxification of malachite green by an engineered polyphenol oxidase at high temperature. *Journal of Cleaner Production*, *328*, p. 129437. https://doi.org/10.1016/j.jclepro.2021.129437

MEINERTZ, J., STEHLY, G., GINGERICH, W. and ALLEN, J., 1995. Residues of [14C]-malachite green in eggs and fry of rainbow trout, *Oncorhynchus mykiss* (Walbaum), after treatment of eggs. *Journal of Fish Diseases,* 18**,** 239-248. https://doi.org/10.1111/j.1365-2761.1995.tb00299.x

[Downloaded from ijaah.ir on 2024-10-12]

[DOI: 10.52547/ijaah.8.1.41]

Mohamad, S., Liew, H.J., Zainuddin, R.A., Rahmah, S., Waiho, K., Ghaffar, M.A., Nhan, H.T., Loh, J.Y., Lim, L.S., Chang, Y. and Liang, L., 2021. High environmental temperature and low pH stress alter the gill phenotypic plasticity of Hoven's carp *Leptobarbus hoevenii*. *Journal of fish biology*, *99*(1), 206-218. https://doi.org/10.1111/jfb.14712

Novotny, L., 2021. Respiratory Tract Disorders in Fishes. *Veterinary Clinics: Exotic Animal Practice*, *24*(2), 267-292. https://doi.org/10.1016/j.cvex.2021.01.001

PEREZ-ESTRADA, L., AGÜERA, A., HERNANDO, M., MALATO, S. and FERNÁNDEZ-ALBA, A., 2008. Photodegradation of malachite green under natural sunlight irradiation: kinetic and toxicity of the transformation products. *Chemosphere,* 70, 2068-2075. https://doi.org/10.1016/j.chemosphere.2007.09.008

Pipoyan, D., Stepanyan, S., Beglaryan, M., Stepanyan, S. and Mantovani, A., 2020. Health risk assessment of toxicologically relevant residues in emerging countries: A pilot study on Malachite Green residues in farmed freshwater fish of Armenia. *Food and Chemical Toxicology*, *143*, p.111526. https://doi.org/10.1016/j.fct.2020.111526

Roberts, H. and Palmeiro, B.S., 2008. Toxicology of aquarium fish. *Veterinary clinics of North America: exotic animal practice*, *11*(2), 359-374. https://doi.org/10.1016/j.cvex.2007.12.005

Shahrani, M., Azari Takami, G., Sharif Rohani, M., Motallebi, A. and Yazdani Sadati, M., 2021. Antifungal effects of alcoholic extract of *Thymus vulgaris* on Siberian sturgeon (*Acipenser baerii*) eggs compared with malachite green effects. *Iranian Journal of Fisheries Sciences*, *20*(1), 218-229.

Sharma, R., Jindal, R. and Faggio, C., 2021. *Cassia fistula* ameliorates chronic toxicity of cypermethrin in *Catla catla*. *Comparative Biochemistry and Physiology Part C: Toxicology & Pharmacology*, *248*, p.109113. https://doi.org/10.1016/j.cbpc.2021.109113

Shivalingu, T. and Jayabhaye, U.M., 2021. Effect of Organochlorine Pesticides on Liver Histopathology of the Common Carp *Cyprinus carpio*. *Annals of the Romanian Society for Cell Biology*, *25*(6), 19574-19583.

Shourbela, R., Tohamy, H. and El-Hawarry, W., 2020. Induced spawning of African catfish (*Clarias gariepinus* Burchell 1822) after pre-spawning prophylactic disinfection; the breeding performance and tissue histopathological alterations are under scope. *Iranian Journal of Fisheries Sciences*, *19*(1), 309-324.

Shukla, D., Das, M., Kasade, D., Pandey, M., Dubey, A.K., Yadav, S.K. and Parmar, A.S., 2020. Sandalwood-derived carbon quantum dots as bioimaging tools to investigate the toxicological effects of malachite green in model organisms. *Chemosphere*, *248*, p.125998. https://doi.org/10.1016/j.chemosphere.2020.125998

[Downloaded from ijaah.ir on 2024-10-12]

[DOI: 10.52547/ijaah.8.1.41]

Sinha, R., Jindal, R. and Faggio, C., 2021. Protective effect of Emblica officinalis in *Cyprinus carpio* against hepatotoxicity induced by malachite green: Ultrastructural and molecular analysis. *Applied sciences*, *11*(8), p.3507. https://doi.org/10.3390/app11083507

Southgate, P.J. and Branson, E.J., 2001. Toxins. In *BSAVA Manual of Ornamental Fish* (pp. 213-218). BSAVA Library. https://doi.org/10.22233/9781910443538.26

Srivastava, A.K., Sinha, R., Singh, N.D. and Srivastava, S.D., 1998. Histopathological changes in a freshwater catfish, *Heteropneustes fossilis* following exposure to malachite green. Proceedings of the National Academy of Sciences of India. Section B. *Biological Sciences*, 68, 253–257.

Srivastava, S. J., Singh, N.D., Srivastava, A. K., and Sinha, R., 1995. Acute toxicity of malachite green and its effect on certain blood parameters of a catfish, *Heteropneustes fossilis*. *Aquatic toxicology*, 31(3), 241-247. https://doi.org/10.1016/0166-445X(94)00061-T

Srivastava, S., Sinha, R. and Roy, D., 2004. Toxicological effects of malachite green. Aquatic Toxicology, 66, 319–329. https://doi.org/10.1016/j.aquatox.2003.09.008

Sudova, E., Machova, J., Svobodova, Z. and Vesely, T., 2007. Negative effects of malachite green and possibilities of its replacement in the treatment of fish eggs and fish: a review. *Veterinarni medicina*, *52*(12), p.527. https://doi.org/10.17221/2027-VETMED

Sun, Y., Zhang, Y., Li, W., Zhang, W., Xu, Z., Dai, M. and Zhao, G., 2021. Combination of the endophytic manganese-oxidizing bacterium *Pantoea eucrina* SS01 and biogenic Mn oxides: An efficient and sustainable complex in degradation and detoxification of malachite green. *Chemosphere*, *280*, p.130785. https://doi.org/10.1016/j.chemosphere.2021.130785

Töre, Y., Ustaoğlu, F., Tepe, Y. and Kalipci, E., 2021. Levels of toxic metals in edible fish species of the Tigris River (Turkey); threat to public health. *Ecological Indicators*, *123*, p.107361. https://doi.org/10.1016/j.ecolind.2021.107361

Van Heerden, E., Van Vuuren, JHJ and Steyn, G., 1995. LC_{50} determination for malachite green and formalin on rainbow trout (*Oncorhynchus mykiss*) juveniles. *Water SA*, *21*(1), 87-94.

Viana, H.C., Jesus, W.B., Silva, S.K.L., Jorge, M.B., Santos, D.M.S. and Neta, R.N.F., 2021. Aggregation of hepatic melanomacrophage centers in *S. herzbergii* (Pisces, Ariidae) as indicators of environmental change and well-being. *Arquivo Brasileiro de Medicina Veterinária e Zootecnia*, *73*, 868-876. https://doi.org/10.1590/1678-4162-12327

Viana, N.P., da Silva, L.C.M., Portruneli, N., Soares, M.P., Cardoso, I.L., Bonansea, R.I., Goulart, B.V., Montagner, C.C., Espíndola, E.L.G., Wunderlin, D.A. and Fernandes,

[Downloaded from ijaah.ir on 2024-10-12]

[DOI: 10.52547/ijaah.8.1.41]

M.N., 2022. Bioconcentration and toxicological impacts of fipronil and 2, 4-D commercial formulations (single and in mixture) in the tropical fish, *Danio rerio*. *Environmental Science and Pollution Research*, *29*(8), 11685-11698. https://doi.org/10.1007/s11356-021-16352-6

YADAV, R. and SINGH, J., 2011. Effect of malachite green on the skin epidermis of a gold fish Carassius auratus. *Journal of Experimental Zoology, India,* 14, 273-279.

Yalsuyi, A.M., Vajargah, M.F., Hajimoralo, A., Galangas, M.M., Prokic, M. and Faggio, C., 2021. Can Povidone-Iodine (Betadine) Act On The Survival Rate and Gill Tissue Structure of Oranda Goldfish (*Carassius Auratus*)?. https://doi.org/10.21203/rs.3.rs-867944/v1

[Downloaded from ijaah.ir on 2024-10-12]

[DOI: 10.52547/ijaah.8.1.41]