Research Article

# Comparative histomorphology of epidermis of head and caudal peduncle in *Otolithes ruber*, *Huso huso* and *Pangasius hypophthalmus* fish

**M. Mohamed[1], R. Abdi[1*], M.T. Ronagh[1], M.A. Salari - Ali Abadi[1], Z. Basir[2]**

[1]Department of Marine Biology, Faculty of Marine Science, Khorramshahr University of Marine Science and Technology, Khorramshahr, Iran

[2]Department of Basic Sciences, Faculty of Veterinary Medicine, Shahid Chamran University of Ahvaz, Ahvaz, Iran

**Received:** March 2021 **Accepted:** August 2021

## Abstract

Three species of fish including, macroscopic scaled fish as *Otolithes rube*r, microscopic scaled sturgeon as *Huso huso* and free scaled cat fish as *Pangasius hypophthalmus* were prepared and specimen of dorsal of head and caudal peduncle were carried out. Routine procedures of tissues preparation followed and paraffin sections stained with (H&E) and (PAS). Results showed, epidermis formed non keratinized stratified squamous epithelium with epidermis, lymphocytes, goblet cells, taste bud and club cells. The epidermis thickness of the head skin was higher than that of the caudal peduncle, as demonstrated by image analysis using light microscopy. Goblet cells were along the superficial cells layers and their distributions were varied. In histomorphometric studies by PAS staining the highest number of these cells were seen in head of *O. ruber* and the lowest were seen in the caudal peduncle of *P. hypophthalmus*. Most of them were seen from the middle to surface layer of the epidermis. Club cells, with large nucleus, mostly evident in the deep and middle layer of the epidermis, being the largest cells within the epithelium. The highest numbers of these cells (61.8 ± 2.16) were found in head region of *P. hypophthalmus*. Taste buds as a sensory organ were not seen in caudal peduncle of *O. ruber* and *H. huso*. Based on the results of this study, epidermis had similarities in cell type and differences in their numbers that could be justified by the presence or absence of scales.

***Corresponding author's Email:** abdir351@gmail.com

**Keywords**: Histomorphology, Skin, *Otolithes ruber*, *Huso huso*, *Pangasius hypophthalmus*





[ DOR: 20.1001.1.2345315.2021.7.1.1.6 ]

[ DOI: 10.52547/ijaah.7.1.10 ]

## Introduction

Fish skin is one of the largest organs of the body and provide complete coverage, responsible for the maintenance of internal exchanges (Guardiola *et al*., 2014.). Also, skin with mucous plays an important role in fish health (Jung and Tonn, 2011). Mucous secreting cells are single extracellular glands that have produced the slimy body surface of fish. They are responsible for the secretion of mucous in the epidermis of fish (Raj *et al*., 2011). It can be very sensitive to chemicals, water, and physical stress. The thickness of the skin and each of its constituent layers varies between different species and even within one species (Zhou *et al*., 2014). Age, season, body different part, and environmental conditions are related (Sveen, 2016). In adult the skin of fish has two general layers of epidermis and dermis. The outer epidermal cells maintain their proliferation. In epidermis, the outermost layer of the skin, naturally is mainly secreted by epithelial superficial cells and mostly by mucosal goblet cells (Jensen, 2015). Epidermis thickness in scaleless fish has increased cellular diversity, especially the presence of high alarm cells (Li *et al*., 2010). Mucous secretion is one of the characteristics of the epidermis of all Teleost's and a large number of other aquatic vertebrates. The goblet cells are larger in size than other epithelial cells and have a positive reaction histochemical staining (Richardson, 2013; Wang *et al*., 2016). This study was based on the presence or absence of scales in fish skin. The scales actually protect the skin, muscles and internal organs (Webb and Kimelman, 2008). Cycloid circular scales are large and thick in less developed bony fish such as *H. huso*. In *O. ruber* cycloid circular scales are thin and relatively transparent. Research has also shown that the presence or absence of scales will cause changes in cell structure and the number of layers on the surface of the skin (Jensen, 2015). The present study can answer many questions in the field of pathology, physiology and histology in the executive units of these species studied. Because there is no report available about comparative study of *O. ruber*, *H. huso*, and *P. hypophthalmus* skin histology.

## Materials and methods

### Fish samples

To do this study, three species were collected from different centers and it was considered five numbers for any of male and female fish. The fish were transported alive and anesthetized before sampling with anesthetics. In this study fish used were mature. *O. ruber* was harvested from Bahrekan beach in Hendijan, *H. huso* provided from sturgeon farm center in Dezful and *P. hypophthalmus* collected from Behbahan breeding center for ornamental catfish.

### General histology

Specimens (0.5x0.5 $cm^2$) (Abdi *et al*., 2007) were taken from different parts of head (dorsal head), caudal peduncle and placed in bouin's fixative solution (Basir and Peyghan, 2019). The process of decalcification was done for *H. huso* by formic acid (Kim *et al*., 2008). Next steps including dehydration in various degrees of alcohol and clarified by xylene and paraffin embedding were performed with a tissue




[ DOR: 20.1001.1.2345315.2021.7.1.1.6 ]
[ DOI: 10.52547/ijaah.7.1.10 ]

processor (Amiripour *et al*., 2015). Following embedding in paraffin, cross and longitudinal sections of 4-6 µm were cut by a Leica RM2255 microtome (German) and collected on glass slides and stained with Hematoxylin and Eosin (H & E) and Periodic acid–Schiff (PAS) (Basir *et al*., 2015) then observed and photographed using an Olympus BX50 light microscope (Japan) equipped with a Dino-Lite lens together with Dino-Capture software installed on the computer (Savari *et al*., 2016; Moradkhani *et al*., 2020).

**Statistical analyse**

Data (epiderma thickness, goblet cells, taste buds and club cells number) were statistically analyzed by student t-test to determine differences between head and caudal peduncle skin areas using statistical package for social science (SPSS for Windows; v19) and differences were considered statistically significant when $p < 0.05$ (Liu *et al*., 2017; Basir and Abdi, 2016).

## Results

The results of microscopic studies in all three species showed that skin of head and caudal peduncle consisted of epidermis with non-keratinized stratified squamous epithelium. By histological examination, large spherical and dilated cells were observed in several rows. These cells showed PAS positive reactions are called mucous secreting or goblet cells. As these cells were drawn to the surface of the epidermis, grew larger and increased in size. There were also very large and bulky called club cells in the epidermis. These cells had a large euchromatin nucleus with a large cytoplasm that reacted negatively with PAS staining and thus were well differentiated from goblet cells that responded positively with PAS staining. The shape and number of these cells were reported different. They were found mainly in the middle region, rarely reaching the apical surface and show elongated and globular shapes. In addition, other structure has elongated, oval-shape called taste buds that open to the surface of the skin by pores. Generally, epidermis in the middle layer is characterized by the presence of blood capillaries and underneath the epithelium was a layer of loose connective tissue with fibroblasts and associated by melanophores (Fig. 1-3). In histomorphometric studies, the highest epidermis thickness was in head of *O. ruber* (20 ± 1.58) and the least thickness was in caudal peduncle of *P. hypophthalmus* (8 ± 2). Goblet cells with amount of (155 ± 3.39) in head of *O. ruber* was the greatest and club cells with amount of (7.6 ± 1.51) in caudal peduncle of *H. huso* was the least. Taste buds with the greatest amount of (3.6 ± 1.14) was reported in head of *P. hypophthalmu* and in two *O. ruber* and *H. huso* in caudal peduncle was not observed (Table 1). Significant comparison between the three fish species was measured in two areas studied separately (Table 2). Also Tukey's post-test to determine significant differences between epidermis thickness, taste buds, goblet cells and club cells in three fish species in two areas studied are shown in (Table 3). In the current study, there was no difference in the type and number of cells between males and females.





[ DOR: 20.1001.1.2345315.2021.7.1.1.6 ]

[ DOI: 10.52547/ijaah.7.1.10 ]

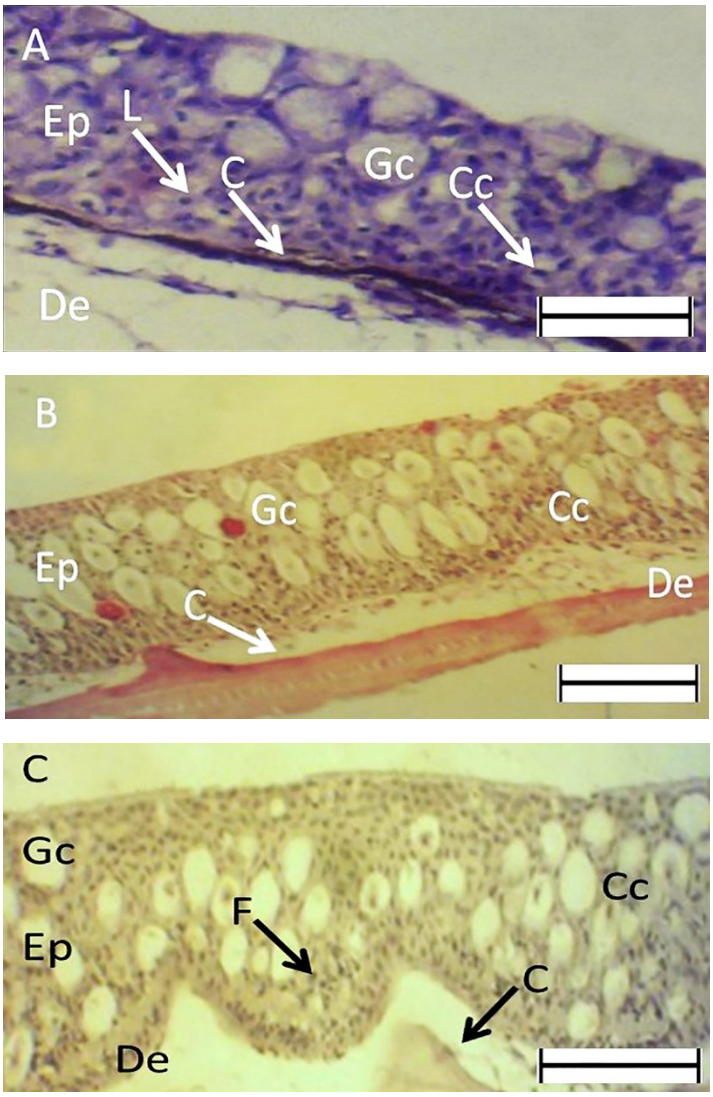


**Figure 1.** Light micrograph of head skin of *O. rube*r (A), *H. huso* (B) and *P. hypophthalmus* (C) (H & E; ×40). Photomicrograph are showing thick epidermis of stratified squamous epithelium tissue composed by epidermis (Ep), lymphocytes (L), dermis (De), goblet cell (Gc), club cells (Cc), fibroblast (F) and melanophores (C), (scale bar = 20µm).

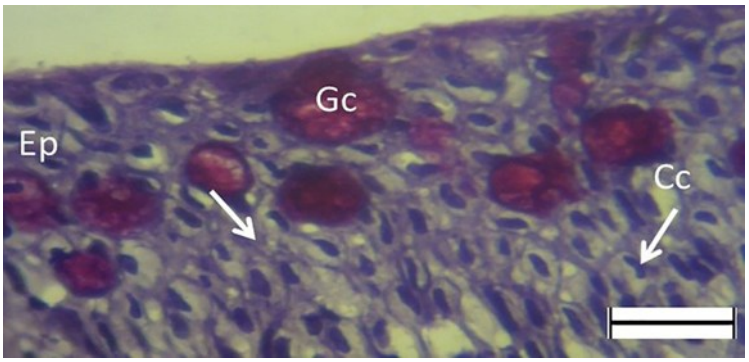


**Figure 2.** Light micrograph of head skin of *O. rube*r (PAS; ×40). Mucus-containing goblet cells (Gc) responded positively to PAS staining and appear purple while the club cells (Cc) are neutral. In this figure, a large goblet cell is secreting mucus material near the surface of the epidermis (Ep). In this form, goblet cells of large size, spherical, oval shape and connective tissue (arrow) were seen, (scale bar = 20µm).




[ DOR: 20.1001.1.2345315.2021.7.1.1.6 ]
[ DOI: 10.52547/ijaah.7.1.10 ]

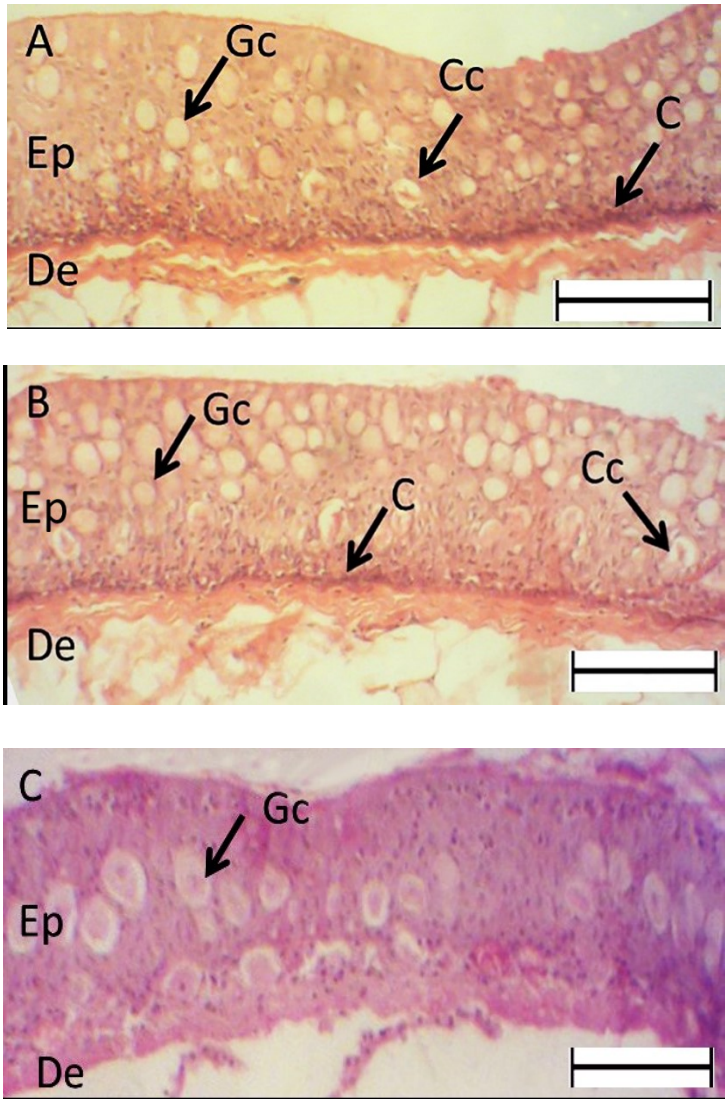


**Figure 3.** Light micrograph of caudal peduncle skin of *O. rube*r (A), *H. huso* (B) and *P. hypophthalmus* (C) (H & E; ×40). Photomicrograph are showing thick epidermis of stratified squamous epithelium tissue composed of epidermis (Ep), dermis (De), goblet cell (Gc), club cells (Cc) and melanophores (C), (scale bar = 20µm).

**Table 1.** (mean ± SEM) of epidermis thickness, goblet cells, club cells and taste buds number (µm$^2$) in different areas of skin at 100µm in *O. ruber*, *H. huso* and *P. hypophthalmus* analyzed by (H & E) staining method

| Region | Epidermis thickness | Goblet cells | Club cells | Taste buds |
|---|---|---|---|---|
| Head | | | | |
| *O. ruber* | 20 ± 1.58 [a] | 155 ± 3.39 [a] | 8.8 ± 0.83 [a] | 1.4 ± 0.54 [a] |
| *H. huso* | 18 ± 1 [b] | 118.6 ± 5.17 [b] | 7.6 ± 1.51 [a] | 2.2 ± 0.83 [b] |
| *P. hypophthalmus* | 17.6 ± 1.14 [b] | 61.8 ± 2.16 [c] | 61.8 ± 2.16 [b] | 3.6 ± 1.14 [c] |
| Caudal peduncle | | | | |
| *O. ruber* | 10 ± 1 [a] | 21 ± 1.58 [a] | 17.4 ± 1.14 [a] | Not seen |
| *H. huso* | 9.4 ± 1.14 [a] | 18.4 ± 1.14 [b] | 20.2 ± 2.38 [b] | Not seen |
| *P. hypophthalmus* | 8 ± 2 [a] | 12.8 ± 2.38 [c] | 22.6 ± 3.36 [c] | 3 ± 1 |

Different letters each column indicate a significant difference ($p$ <0.05).




[ DOR: 20.1001.1.2345315.2021.7.1.1.6 ]
[ DOI: 10.52547/ijaah.7.1.10 ]

**Table 2.** Significant comparison table between the three fish species was measured in terms of the two areas separately

| Region | Epidermis thickness | Goblet cells | Club cells | Taste buds |
|---|---|---|---|---|
| Head | 0.02* | 0.00* | 0.25 | 0.04* |
| Caudal peduncle | 0.12 | 0.00* | 0.02* | - |

*In each column indicate a significant difference in terms of the two areas separately ($p$ <0.05).

**Table 3.** Tukey's post-test to determine significant differences between epidermis thickness, taste buds, goblet cells and club cells in three fish species in head and caudal peduncle areas

| Region | Variable | significant |
|---|---|---|
| Head | Epidermis thickness | |
| | *O. ruber - H. huso* | 0.06 |
| | *O. ruber - P. hypophthalmus* | 0.02* |
| | *H. huso - P. hypophthalmus* | 0.87 |
| Caudal peduncle | Epidermis thickness | |
| | *O. ruber - H. huso* | - |
| | *O. ruber - P. hypophthalmus* | - |
| | *H. huso - P. hypophthalmus* | - |
| Head | Taste buds | |
| | *O. ruber - H. huso* | 0.44 |
| | *O. ruber - P. hypophthalmus* | 0.00* |
| | *H. huso - P. hypophthalmus* | 0.03* |
| Caudal peduncle | Taste buds | |
| | *O. ruber - H. huso* | - |
| | *O. ruber - P. hypophthalmus* | - |
| | *H. huso - P. hypophthalmus* | - |
| Head | Goblet cells | |
| | *O. ruber - H. huso* | 0.00* |
| | *O. ruber - P. hypophthalmus* | 0.00* |
| | *H. huso - P. hypophthalmus* | 0.00* |
| Caudal peduncle | Goblet cells | |
| | *O. ruber - H. huso* | 0.09 |
| | *O. ruber - P. hypophthalmus* | 0.00* |
| | *H. huso - P. hypophthalmus* | 0.00* |
| Head | Club cells | |
| | *O. ruber - H. huso* | - |
| | *O. ruber - P. hypophthalmus* | - |
| | *H. huso - P. hypophthalmus* | - |
| Caudal peduncle | Club cells | |
| | *O. ruber - H. huso* | 0.21 |
| | *O. ruber - P. hypophthalmus* | 0.01* |
| | *H. huso - P. hypophthalmus* | 0.30 |

*In each column indicate a significant difference depending to the measured items in three fish species ($p$ <0.05).

## Discussion

The skin of fish constitutes about 10% of the body weight and the epidermis has an important role as a barrier between the environment and the body of the fish, osmoregulatory processes, protecting the fish against mechanical damage, ectoparasites and pathogenic microorganisms (Al-Banaw *et al*., 2009; Lin *et al*., 2008). Unlike the epidermis of most onshore vertebrates which is covered with a keratinous layer, that of fish remains metabolically active. The epidermis is covered several cell layers thick, and contains a variety of cell types with different properties (Richardson, 2013). The epidermal thickness affected by size, environmental conditions, maturing and physiological status and even in one species in




[ DOR: 20.1001.1.2345315.2021.7.1.1.6 ]
[ DOI: 10.52547/ijaah.7.1.10 ]

different parts of the body (Regueira *et al*., 2016). In the recent study, the highest epidermal thickness in the two head and caudal peduncle regions was reported in *O. ruber*. Researchers believe that presence of scales and multiple layers of mucus secreting cells may be due to the increased thickness of the epidermis compared to the other two species (Stabell and Vegusdal, 2010). For these reasons, the lowest thickness of the epidermis layer in *P. hypophthalmus* is acknowledged. In fish the epidermis cell layers may be variable from 2 to 15 (Cordero *et al*., 2017). In *O. ruber* as a pelagic fish species, the epidermis is frequently thickest in the dorsal areas of the body but in benthic species, the epidermis covering ventral surfaces is often thicker. In confirmation of our findings, other researchers reported that some species such as salmonids, the epidermis is often thicker in non-scaled areas, such as the top of the head, than in scaled areas of the body (Park *et al*., 2010). Melanophores found in the basal region of the epidermis in all three species studied have been reported to be dark cells containing pigments along with a large number of electron-dense granules of melanin pigment that can move into the cytoplasm of the cell to give a favorable staining and protective effect (Guardiola *et al*., 2014). Goblet or mucus-secreting cells were studied in the epidermis of all fish in the present study. They numbers vary greatly with site and species. The size and number of these cells in different species and even in one species were very different depending on the position. The most prominent feature of these cells was PAS staining positive, usually originated in the middle layer of the epidermis and they were massive when they were drawn to the surface. Unlike these, superficial, middle and basal layer epithelial cells and club cells did not respond positively to the PAS staining. The highest and lowest numbers of goblet cells were observed in the head and caudal peduncle in all three species, respectively. The highest number of this cell was reported in macroscopic scaled fish as *O. ruber* in head while, the lowest number of these cells was reported in free scaled fish as *P. hypophthalmus*i in caudal peduncle. The researchers believe that the reason for the increase of these cells in the head area is for easy splitting, floating and prevent damage to this area when searching for food and collision with foreign bodies (Barbosa *et al*., 2010). The classification of goblet cells varies greatly according to the number, shape, and size of the skin tissue, depending on the presence or absence of scales (Naderi *et al*., 2014). Apart from scales, it has been reported that in deep-water fish, goblet cells are more tolerant of adaptation to the lifestyle (Ceballos-Francisco *et al*., 2017). In addition, the number of these cells is more in scaleless area than in other areas of the body (Cordero *et al*., 2015). The thickness of the epidermis layer in each part of the fish's body also depends on the number of goblet cells in that area to secrete mucus to forming lubricate (Halbgewachs *et al*., 2009). In general, as observed in the recent study on the skin of all three different species, there was a higher concentration of goblet cells in the epidermis of the anterior than to the posterior region, because the mucosa tends to return to the back of the animal when moving forward.




[ DOR: 20.1001.1.2345315.2021.7.1.1.6 ]
[ DOI: 10.52547/ijaah.7.1.10 ]

Therefore, the concentration of these cells in the posterior part of the body will be less due to the accumulation of mucus. Histological analysis revealed the presence of club cells in the epidermis of all three species studied. These cells were observed large, round to oval central nucleus, in the middle region of the epidermis and showed no PAS positive reaction. So in this experiment the presence of carbohydrates and non-basophil cytoplasm is detected. Researchers believe that these cells have immune function that protect against general injury, parasites, pathogens, and may also have alarming function as a secondary role (Karlsen *et al*., 2018). According to our finding, these cells in *P. hypophthalmus*i were elongated compared to the other two species. It has also been reported that in the *Plicofollis argyropleuron*, these cells were elongated, whereas they were observed globular in *Ictalurus punctatus* (Lei *et al*., 2012). In any case, the morphology, large size, position and negative reaction to PAS are quite similar to the description of the other species studied (Regueira *et al*., 2016). In histomorphological finding in all three species, taste buds or sensory buds were very different from other studied factors. As reported, in the caudal peduncle only in *P. hypophthalmus* this organ has been seen. Researchers believe that the shape and size of the sensory buds vary in different parts of the body and have specific and protective epithelial cells in each species. Also some researchers reported that the difference in these organs is related to ecomorphological adaptation of fish (Sveen *et al*., 2019).

## Acknowledgment

This study, which was part of Malihe Mahamed, post graduate research, was carried out at Faculty of Marine Science post graduate programme under the supervision of Rahim Abdi. It was financially supported by Deputy of Research and Technology of Khorramshahr University of Marine Science and Technology.

## Conflicts of interest

None of the authors has any conflicts of interest to declare.

## References

Abdi, R., Sheibani, M.T., Adibmoradi, M. and Sharifpour, I., 2007. Histological study of liver and pancreas in adult Otolithes ruber in Bushehr, Iran. *Iranian Scientific Fisheries Journal*, 15(4), 87-96. (In Persian)

Al-Banaw, A., Kenngott, R., Al-Hassan, J.M., Mehana, N. and Sinowatz, F., 2009. Histochemical analysis of glycoconjugates in the skin of a catfish (*Arius Tenuispinis*, Day). *Anatomy Histology Embryology*, 39, 42–50. https://doi.org/10.1111/j.1439-0264.2009.00977.x

Amiripour, L., Abdi, R., Movahedinia, A. and Sahraian, M.R., 2015. Study of Liver and Intestine Tissue Structure in Orange Spotted Grouper (*Epinephelus coioides*) During Larval Development. *Journal of Oceanography*, 6(23), 87-92.

Barbosa, A., Magalhaes, E.J. and Hoffmann, A., 2010. Conspecific and heterospecific alarm





[ DOR: 20.1001.1.2345315.2021.7.1.1.6 ]

[ DOI: 10.52547/ijaah.7.1.10 ]

substance induces behavioral responses in piau fish *Leporinus piau*. *Acta Ichthyology*, 13, 119–126. https://doi.org/10.1007/s10211-010-0081-6

Basir, Z. and Peyghan, R., 2019. Immunohistochemical and ultrastructural study of the effect of different salinities on gill chloride cells of *Cyprinus carpio*. *Iranian Journal of Fisheries Science*, 28 (5), 131-141.

Basir, Z. and Abdi, R., 2016. Histological study of WBC and hematological indices of spotted catshark Chiloscyllium punctatum in Persian Gulf during the cold season. *Journal of Marine Science and Technology*, 14(4), 15-21.

Basir, Z., Hassan, M., Mahabadi, M.K., Mesbah, M. and Abdi, R., 2015. Histomorphometric and Histochemistry of Mucous Secreting Cells in Different Parts of Skin in Shabut (Barbusgrypus, Heckel 1843). *Journal* of *Applied Environmental* and *Biological Sciences*, *5*(10S), 80-85.

Ceballos-Francisco, D., Cordero, H., Guardiola, F.A., Cuest, A. and Esteban, M.A., 2017. Healing and mucosal immunity in the skin of experimentally wounded gilthead seabream (*Sparus aurata L*). *Fish & shellfish immunology*, 71, 210–219. https://doi.org/10.1016/j.fsi.2017.10.017

Cordero, H., Brinchmann, M.F., Cuesta, A., Meseguer, J. and Esteban, M.A., 2015. Skin mucus proteome map of European sea bass (*Dicentrarchus labrax*). *Proteomics*, 15, 4007–4020. https://doi.org/10.1002/pmic.201500120

Cordero, H., Ceballos-Francisco, D., Cuesta, A. and Esteban, M.A., 2017. Dorso-ventral skin characterization of the farmed fish gilthead seabream (*Sparus aurata*). PLoS ONE, 12(6), e0180438. https://doi.org/10.1371/journal.pone.0180438

Guardiola, F.A., Cuesta, A., Abellan, E., Meseguer, J. and Esteban M.A., 2014. Comparative analysis of the humoral immunity of skin mucus from several marine teleost fish. *Fish & shellfish immunology*, 40, 24–31. https://doi.org/10.1016/j.fsi.2014.06.018

Guardiola, F.A., Cuesta, A., Arizcun, M., Meseguer, J. and Esteban, M.A., 2014. Comparative skin mucus and serum humoral defence mechanisms in the teleost gilthead seabream (*Sparus aurata*). *Fish & shellfish immunology*, 36, 545–551. https://doi.org/10.1016/j.fsi.2014.01.001

Halbgewachs, C.F., Marchan, T.A., Kusch, R.C., Chivers, D.P., 2009. Epidermal club cells and the innate immune system of minnows. *Biological Journal of the Linnean Society*, 98, 891–897. https://doi.org/10.1111/j.1095-8312.2009.01328.x

Jensen, L.B., 2015. Effect of temperature and diet on wound healing in Atlantic salmon (*Salmo salar* L.). *Fish Physiology* and *Biochemistry,* 41, 1527–1543. https://doi.org/10.1007/s10695-015-0105-2

Jung, J.A. and Tonn, W.M., 2011. Alarm substances elicit limited population - level responses in fathead minnow. *Ecology of*





[ DOR: 20.1001.1.2345315.2021.7.1.1.6 ]

[ DOI: 10.52547/ijaah.7.1.10 ]

*Freshwater Fish*, 20, 220–230. https://doi.org/10.1111/j.1600-0633.2010.00481.x

Karlsen, C., Ytteborg, E., Timmerhaus, G., 2018. Atlantic salmon skin barrier functions gradually enhance after seawater transfer. *Scientific Reports,* 8, 95-101. https://doi.org/10.1038/s41598-018-27818-y

Kim, C.H., Park, M.K., Kang, E.J., 2008. Minute tuber- cles on the skin surface of larvae in the Korean endemic bit- terling, *Rhodeus Pseudosericeus*. *Journak of Applied Ichthyology*, 24, 269–275. https://doi.org/10.1111/j.1439-0426.2007.01030.x

Lei, F.Z., Jiang, J.P., Li, C., Xie, F., 2012. Histological observation of skinfrom three species of Megophryinae. *Chinese Journal of Zoology*, 47(3),20-7, 2012.

Li, X.J., Peng, X.L. and Qiao, Z.G., 2010. Studies on the types,distribution andsecretion of mucous cells in the skin and gill of *Silurus asotu*. *Journal of Shanghai Ocean University*, 19(6), 751-5.

Lin, X., Zhang, W.N., Lin, S.G., Jiang, D.P. and Wang, S.K., 2008. Type anddistribution of mucous cells in skin, gills and digestive tracts of *Anguilla anguilla*. *Fujian Journal of Agricultural* Sciences, 1, 39-43.

Liu, Y., Xiao, Q., Yang, S., Zhao, L., Fu, H., Du, J., Du, Z., Yan, T. and Wu, H., 2017. Characterization of hematopoiesis in Dabry's sturgeon (*Acipenser dabryanus*). *Aquaculture and* Fishery *Sciences*, 2(6), 262-8. https://doi.org/10.1016/j.aaf.2017.10.007

Moradkhani, A., Abdi, R., Salari-Ali Abadi, M.A., Nabavi, S. and Basir, Z., 2020. Quantification and description of gut-associated lymphoid tissue in, shabbout, *Arabibarbus grypus* (actinopterygii: cypriniformes: cyprinidae), in warm and cold season. *Acta Ichthyologica et Piscatoria*, 50(4), 423-432. https://doi.org/10.3750/AIEP/02910

Naderi, S., Abdi, R., Navabi, M.B., Movahedinia, A., 2014. Distribution Pattern of Main Mucus Secretory Cells in Different Parts of Epiderm in Epinephelus coioides. *International Journal of Scientific Engineering and Technology*, 3(5), 630-633.

Park, J.Y., Oh, M.K, Kang, E.J., Kim, C.H. and Beon, M.S., 2010. On the vascularization and structure of the skin of a Korean bullhead *Pseudobagrus brevicorpus* (Bagridae, Teleostei) based on its entire body and appendages. *Journal of Applied Ichthyology*, 26, 64–70. https://doi.org/10.1111/j.1439-0426.2009.01354.x

Raj, V.S., Fournier, G., Rakus, K., Ronsmans, M., Ouyang, P., Michel, B., Delforges, C., Costes, B., Farnir, F., Leroy, B., Wattiez, R., Melard, C., Mast, J., Lieffrig, F. and Vanderplasschen, A., 2011. Skin mucus of *Cyprinus carpio* inhibits cyprinid herpesvirus 3 binding to epidermal cells. *Veterinary Resaerch*, 42, 92-1001. https://doi.org/10.1186/1297-9716-42-92

Regueira, E., Davila, C. and Hermida, G.N., 2016. Morphological changes in skinglands during development in *Rhinella arenarum*





[ DOR: 20.1001.1.2345315.2021.7.1.1.6 ]

[ DOI: 10.52547/ijaah.7.1.10 ]

(Anura: Bufonidae). *Anatomical Record*, 299(1), 141-56. https://doi.org/10.1002/ar.23284

Richardson, R., 2013. Adult zebrafish as a model system for cutaneous wound healing research. *Journal of Investigative* Dermatology, 133, 1655–1665. https://doi.org/10.1038/jid.2013.16

Richardson, R. 2013. Re-epithelialization of cutaneous wounds in adult zebrafish combines mechanisms of wound closure in embryonic and adult mammals. *Development,* 143, 2077–2088.

Savari, S., Safahieh, A., Archangi, B., Savari, A. and Abdi, R., 2016. Evaluation of acetylcholinesterase transcript level as a biomarker of methylmercury in orange spotted grouper *(Epinephelus coioides)* brain. *Iranian Journal of Fisheries Sciences*, 15(2), 898-912.

Stabell, O.B. and Vegusdal, A., 2010. Socializing makes thick-skinned individuals: on the density of epidermal alarm substance cells in cyprinid fish, the crucian carp (*Carassius carassius*). *Journal of Comparative Physiology* A, 196, 639–647. https://doi.org/10.1007/s00359-010-0550-4

Sveen, L.R., 2016. Impact of fish density and specific water flow on skin properties in Atlantic salmon (*Salmo salar* L.) post-smolts. Aquaculture, 464, 629–637. https://doi.org/10.1016/j.aquaculture.2016.08.012

Sveen, L.R., Timmerhaus, G. and Krasnov, A., 2019. Wound healing in post-smolt Atlantic salmon (*Salmo salar* L.). *Scientific Report,* 9, 35-45. https://doi.org/10.1038/s41598-019-39080-x

Wang, X., Jing, H., Li, J., Ma, Q., Liu, K. and Song, Z., 2016. Development of 26SNP markers in dabry's sturgeon (*Acipenser dabryanus*) based on high-throughput sequencing. *Conservation Genetics Resources*, 9(2), 234-240. https://doi.org/10.1007/s12686-016-0651-7

Webb, A.E. and Kimelman, D., 2008. Analysis of early epidermal development in Zebrafish. *Methods in Molecular Biology*, 289, 137–146. https://doi.org/10.1385/1-59259-830-7:137

Zhou, B., Lu, J., Xu, F., Chen, X. and Ye, H., 2014. Effects of temperature on oxygen consumption rate of Dabry's sturgeon juvenile. *Journal of Agriculture Science*, 27(5), 2236-9.





[ DOR: 20.1001.1.2345315.2021.7.1.1.6 ]

[ DOI: 10.52547/ijaah.7.1.10 ]